



## *Internationally indexed journal*

Indexed in Chemical Abstract Services (USA), Index copernicus, Ulrichs Directory of Periodicals, Google scholar, CABI ,DOAJ , PSOAR, EBSCO , Open J gate , Proquest , SCOPUS , EMBASE ,etc.



### *Rapid and Easy Publishing*

*The "International Journal of Pharma and Bio Sciences" (IJPBS) is an international journal in English published quarterly. The aim of IJPBS is to publish peer reviewed research and review articles rapidly without delay in the developing field of pharmaceutical and biological sciences*



#### **Pharmaceutical Sciences**

- Pharmaceutics
- Novel drug delivery system
- Nanotechnology
- Pharmacology
- Pharmacognosy
- Analytical chemistry
- Pharmacy practice
- Pharmacogenomics



#### **Biological Sciences**

- Polymer sciences
- Biomaterial sciences
- Medicinal chemistry
- Natural chemistry
- Biotechnology
- Pharmacoinformatics
- Biopharmaceutics
- Biochemistry
- Biotechnology
- Bioinformatics
- Cell biology
- Microbiology
- Molecular biology
- Neurobiology
- Cytology
- Pathology
- Immunobiology

**Indexed in Elsevier Bibliographic Database  
(Scopus and EMBASE)**

**SCImago Journal Rank 0.288**

**Impact factor 2.958\***

Chemical Abstracts  
Service ([www.cas.org](http://www.cas.org))



A division of the American Chemical Society

**CODEN IJPBJ2**



## Elsevier Bibliographic databases (Scopus & Embase)

**SNIP** value – 0.77

**SJR** - 0.288

**IPP** - 0.479

*SNIP – Source normalised impact per paper*

*SJR – SCImago Journal rank*

*IPP – Impact per publication*

*Source – [www.journalmetrics.com](http://www.journalmetrics.com)*

*(Powered by scopus (ELSEVIER))*



**LUND**  
UNIVERSITY



JACKSONVILLE STATE UNIVERSITY  
Jacksonville State University  
Houston Cole Library  
USA (Alabama)



Oxford, United Kingdom

INDEX COPERNICUS  
INTERNATIONAL

*And indexed/catalogued in  
many more university*



\*Instruction to Authors visit [www.ijpbs.net](http://www.ijpbs.net)

For any Queries, visit "contact" of [www.ijpbs.net](http://www.ijpbs.net)



## CLINICO MYCOLOGICAL PATTERN OF FUNGAL RHINOSINUSITIS - A STUDY FROM A TERTIARY CARE CENTRE

ANANDHILAKSHMANAN\*<sup>1</sup>, ANANDHALAKSHMI.S<sup>2</sup> AND SELVARAJAN G<sup>3</sup>

<sup>1</sup> Department of Microbiology, SRM Medical College Hospital & Research Centre, TamilNadu, 603203.

<sup>2</sup> Department of Physiology, SRM Medical College Hospital & Research Centre, TamilNadu, 603203.

<sup>3</sup> Department of Otolaryngology, Madras Medical College, Rajiv Gandhi Hospital, TamilNadu, 600001.

### ABSTRACT

Nose and Paranasal sinuses are being constantly exposed to the environment. Hence fungus are increasingly being implicated in the etiology of rhinosinusitis. It is a cause of morbidity and mortality, especially when it is invasive fungal sinusitis. To study the fungal profile of sinusitis in a tertiary care centre in South India and correlate with clinical findings and histopathology. Classification into clinical types was also attempted. Samples were received from suspected cases of fungal sinusitis, confirmed by radiography (heterogenous opacity with sinus expansion CT scan) from the Department of Otorhinolaryngology, SRM Medical College and Hospital. The endoscopic aspirates of tissue samples were examined microscopically and subjected to culture. Species identification was done by standard microbiological methods. Histopathological (HPE) findings were also correlated. A total of 84 patients were enrolled in the study, which included 50 (60%) males and 34 (40%) females. The maximum number of specimen (44) received were in the age group of 21-40 years. Among the 84 specimens, 54 were culture positive. *Aspergillus* spp (40%) was reported to be the major isolate, *Aspergillus flavus* being (63%), followed by *Aspergillus fumigates* (29%). Allergic Fungal RhinoSinusitis (AFRS) was the most common clinical type (66%) and in the majority of these cases the causative agent was *Aspergillus flavus*. Fungal infections of the paranasal sinuses are not uncommon, especially in tropical region, hence it is important to identify early and treat patients timely to prevent complications.

**KEYWORDS:** Fungal rhinosinusitis, *Aspergillus flavus*, *Aspergillus fumigates*.



**ANANDHILAKSHMANAN**

Department of Microbiology, SRM Medical College Hospital  
& Research Centre, TamilNadu- 603203

## INTRODUCTION

Fungal RhinoSinusitis (FRS) is broadly defined as the spectrum of pathologic condition associated with sino-nasal inflammation that is related to the presence of fungi. Though it is widely held that mycotic infections of the nose and paranasal sinuses are not common, most agree that their frequency has been increasing over the past two decades. Several factors contribute to this apparent increase in incidence of the disease. The foremost reason being technical advance in mycology, histopathology and radiology that have improved the detection of fungus in sinuses and paranasal regions. The second factor relates to the change in the micro environment in the nose and sinuses (alternation of normal bacterial flora) due to the increasing use of broad spectrum antibiotics and topical nasal preparation. Third, the increase in the frequency of invasive mycotic infection is readily linked to the growing number of immunosuppressed individuals. This includes patient with diabetes mellitus, those on immune suppressive drugs after organ transplantation and reduced immune response following radiation or chemotherapy. Fungal sinusitis was originally classified as invasive and non-invasive. However, the recent revised classification covers the entire spectrum of changes produced for precisely identifying the various lesions [3].

### **Classification of clinical presentation**

Broadly fungal infections of the paranasal sinuses is classified as Non Invasive and Invasive which present clinically as ,

- Allergic fungal rhinosinusitis (AFRS)
- Fungal ball
- Chronic indolent sinusitis
  - Granulomatous type
  - Chronic invasive type
- Acute invasive (AI) fungal sinusitis, depending on the pathophysiology and clinical features .

### **1. Allergic fungal rhinosinusitis(AFRS)**

Patient with a combination of the following findings were diagnosed as having AFS as per the diagnostic criteria described by Bent and Kuhn.

- Positive culture/fungal stain.

- Demonstration of fungal hyphae in the allergic mucin.
- Radiological findings (Heterodense mass lesion).

### **2. Fungal ball**

The disease is commonly unilateral involving the maxillary /sphenoid rarely ethmoid and frontal sinuses. There is presence of dense accumulation of fungal hyphae in the sinus cavities.

### **3. Chronic indolent sinusitis Granulomatous type**

A granulomatous response is seen with considerable fibrosis on histopathology. A non-caseating granuloma with foreign body or Langerhans type giant cell may be observed, sometimes vasculitis , vascular proliferation and perivascular fibrosis are also seen. Hyphae are scanty , on many occasions.

### **Chronic invasive type**

Characterized by dense accumulation of hyphae, sometimes with vascular invasion, chronic or sparse inflammatory reaction and associated with orbital apex syndrome common among diabetics .More than 80% have frontoethmoidal sinus involvement.

### **4. Acute invasive fungal rhinosinusitis**

The characteristic of this life threatening category in immunosuppressed patients is an invasion of tissue and duration of illness below 4 weeks.

## AIM AND OBJECTIVES

To study the fungal profile of all the rhino sinusitis patients in a tertiary care centre in South India and correlate with clinical findings and histopathology. Classification into clinical types was also attempted.

## MATERIALS AND METHODS

In the current study, a total number of 84 samples were received from suspected cases of fungal sinusitis from the Department of Otorhinolaryngology, SRM Medical College and Hospital during a two year period. All the

patients who were clinically diagnosed as sinusitis and confirmed by computerized tomography (CT) scan (heterogenous opacity with sinus expansion CT scan) were included in the study, irrespective of the age. The sample collected were mucin, tissue and/or fungal ball from the infected sinus cavities, the samples were taken during functional endoscopic sinus surgery (FESS). They were collected in a sterile container with sterile normal saline for microbiological study and another in formalin for histopathological study. The samples obtained were processed as per routine mycological procedure. The debrided tissue received from the patients was first minced into tiny bits in a sterile petri dish using a sterile blade. A drop of 10% KOH (potassium hydroxide) was put on a piece of this tissue on a slide to look for fungal hyphae microscopically. The remaining bits of tissue were inoculated in fungal culture media like Sabouraud's Dextrose Agar in two tubes. One tube was inoculated at 37°C. and the other tube at 25°C. The tubes were incubated for 3 weeks. If fungal growth appeared, morphological study and identification of the isolates was done using Lacto Phenol Cotton Blue stain mount. A slide culture mount was also examined by the same method. Species identification was done by standard microbiological methods. We arrived at a diagnosis by the practice of clinical mycology, that is correlating the lab finding with clinical features. Histopathological examination was done after staining with hematoxylin and eosin stain and with special fungal stain - Gomori Methanamine silver stain and periodic schiff stain and the findings were also correlated. The selected cases were examined and a detailed history if suffering from asthma, any other allergy or previous sinus surgery, was also recorded. History of diabetes or any other immunocompromised condition was also noted. All patients on treatment were called for follow up and repeat nasal endoscopy was performed to access the nasal mucosa. The data were entered in Microsoft excel spreadsheet and results were analyzed.

## RESULTS

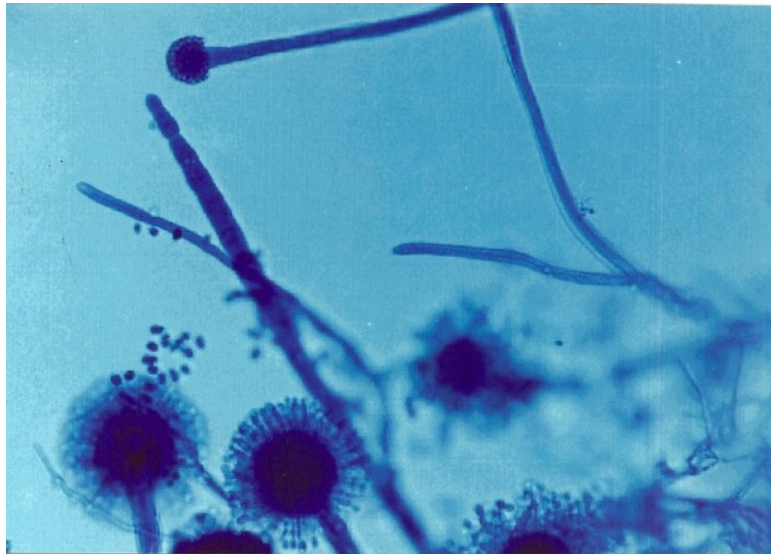A total of 84 patients suspected to suffer from FRS were enrolled in the study, which

included 50 (60%) males and 34 (40%) females, ratio of 1.5:1. The age of the patients in the present study ranged from 16 years to 80 years. Majority of the patients in the study group were above 20 years. The maximum number of specimens (44) received was in the age group of 21-40 years. Out of 84 samples, 54 were culture positive. Among the 84 patients, 24 (29%) were immunocompromised and 60 (71%) were immunocompetent. It was interesting to note that all the patient in the immune-compromised group were positive for fungus; while 30 (50%) immunocompetent patients were culture positive. 15 specimens were KOH positive, but culture negative. Another 15 specimens were both KOH and culture negative. *Aspergillus* spp was the commonest pathogen isolated (n=38/54), a rate of 70%. The commonest species in *Aspergillus* group was *Aspergillus flavus* (24/38) which was 29% and *Aspergillus niger* (3/38), 8%. It was noted that all the specimens that showed evidence of fungi in HPE, were also positive for KOH examination and culture. Table/ Fig [1] shows the various clinical presentations of fungal sinusitis. The most common form of mycosis noted was AFRS, being 56 cases (66%). All four patients in the invasive group were immunocompromised, consisting of two renal transplant patients and two with uncontrolled diabetes. There was no correlation between the type of immunocompromised state and the type of fungal growth. Among all the fungal isolates *Aspergillus* species was the most common. The LPCP mount of *Aspergillus flavus* is shown in Table/ Fig [2]. All patients with fungal infection after surgical debridement received oral voriconazole for a month and followed up for another month till the mucosa was healthy, those with invasive type of disease after surgical debridement received Amphotericin B followed by voriconazole for a month. The treatment was stopped after the endoscopy showed a healthy nasal mucosa. Follow up: In our study the patients having invasive fungal infection had a longer follow up with close monitoring of their underlying risk factors like control of diabetes, assessment of renal function tests for patients who were put on Amphotericin B. The outcome of all the patients was good, after sinus debridement followed by antifungal treatment.

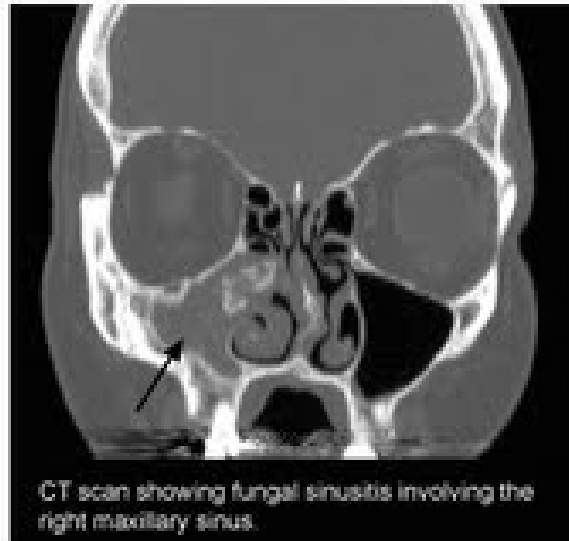
**Table/ Figure – 1**  
**Clinical classification of fungal sinusitis among the positive isolates**

Isolates	Number	Clinical Presentation	Number
<i>Aspergillusflavus</i>	24	AFRS	11
		Fungal ball	8
		Chronic indolent (granulomatous)	5
<i>Aspergillusfumigatus</i>	11	AFRS	5
		Fungal ball	4
		Chronic indolent (granulomatous)	2
<i>Aspergillusniger</i>	3	AFRS	1
		Fungal ball	2
<i>Candida sp</i>	4	AFRS	4
<i>Rhizopus</i> sp	3	Chronic Indolent (invasive type)	3
<i>Mucor</i>	1	Acute invasive	1
<i>Cladophialophora</i> sp	2	AFRS	2
<i>Acremonium</i> sp	2	AFRS	1
		Fungal ball	1
<i>Fusariumsolani</i>	1	AFRS	1
<i>Alternaria</i>	1	Fungal ball	1
<i>Curvularia</i>	1	AFRS	1
<i>Penicillium</i> sp	1	Chronic indolent (granulomas)	1
Total	54		

**Table/ Figure - 2**  
**LPCB mount of *Aspergillusflavus***



**Table/ Figure 3**  
**CT SCAN showing fungal sinusitis involving the right maxillary sinus**



## DISCUSSION

A variety of host and environmental factors contribute to the development of fungal sinusitis. Sinus obstruction with impaired ventilation is the predisposing factor for the conversion of ubiquitous organisms from saprophytic to pathogenic form. The incidence of fungal rhinosinusitis has been previously reported to be approximately 10% of all patients requiring surgery of the nose and sinuses [1]. Similar results (10.75%) were noted by Grevel et al in their study [2]. The current study shows the incidence to be higher than earlier studies. The reason for higher incidence could be due to various factors, most important being criteria taken for the selection of cases and collection of specimens. Selection of cases for the study was based on strict clinical and radiological assessment. All the clinically suspected invasive fungal sinusitis were isolated and confirmed histopathologically. An ideal approach of diagnostic fungal sinusitis incorporates the three components; clinical diagnosis, microscopic examination and culture of properly collected specimens with histopathology of tissue or the cheesy material obtained from sinuses during FESS. A high rate of fungal isolation in our study highlights the importance of the above factors. Microscopic examination is the most definite and rapid means of establishing a diagnosis of

FRS. In addition, it also allows preliminary diagnosis regarding the probable cause and identifying accurately the fungus to the genus level. Determining the cause strongly influences a decision to use immediate and aggressive surgical intervention as in case of zygomycosis. Failure of the fungus to grow on culture is common; with only 23-50% of the specimens resulting in fungal growth [4]. In our study only (30) 36% were culture negative. A data from the Mayo clinic suggests that normal individuals may have two different fungal forms in their nasal cavity. Thus, colonization of the lower respiratory tract can lead to opportunistic and local infections. One mechanism by which this occurs is by blockage of osteomeatal complex and the development of relatively anaerobic environment. The low pH and decreased mucociliary clearance traps the fungal spores leading to their spread [5]. Out of the total fungi isolated from our patients, *Aspergillus* species topped the list(70%). Other authors from India have also reported *Aspergillus* species to be the most common isolate [6,7,8]. Among the *Aspergillus* species seen in our study *Aspergillus flavus*[(24 (63%))] was the most frequently isolated followed by the *Aspergillus fumigatus*[11(29%)]. Difference in the species isolated in our study and those of others draws our attention to the fact that

the prevalence of *Aspergillus* species has been found to vary from place to place. In a similar study done in Germany by Vennwald et al reported *Aspergillus fumigates* to be more common than the other species, while in a study in Malaysia, *Aspergillus niger* was the most common species followed by *Aspergillus flavus* [9]. Zygomycetes occupied the second place (7.5%) among the fungi isolated in the present study, three of them being *Rhizopus* spp and one being *Mucor* spp. *Rhizopus* spp is predominantly an opportunistic fungus causing disease in human. The site from which *Rhizopus* is most commonly isolated is sinuses and rhinocerebral structure [10]. In our study all three *Rhizopus* species isolated were from cases of sinusitis. Studies done by various authors have also found *Rhizopus* spp as a predominant cause of sinusitis only next to *Aspergillus*. Out of the four candida isolated three were from immunocompromised (two type 2 Diabetes Mellitus cases and one post renal transplant case) and one an immunocompetent patient. Apart from *Aspergillus* and *Rhizopus* which contributed to the majority of the isolates The other moulds in the present study consisted of dematiaceous fungi (2 of *Cladophialophora* and one each of *Curvularia* and *Alternaria*) and hyalohyphomycetes other than *Aspergillus*, (two *Acremonium* one each of *Penicillium* and *Fusarium*). Phaeohyphomycotic sinusitis is caused mainly by the species of the dematiaceous genera *Alternaria*, *Curvularia* and *Bipolaris*. Dematiaceous fungi appear to be the most common cause of non-invasive fungal sinusitis in North America [11]. In our study also dematiaceous fungi produced only non-invasive sinusitis but were not the most common cause of sinusitis. the ability of moulds to form spores in situ in human hosts, including the paranasal sinuses, has been recognized for many years, more so for fungal balls caused by *Aspergillus* spp, *Fusarium* spp. A recent study has shown that sporulation appears to be an integral part of the infectious process of moulds like *Acremonium* [12]. *Acremonium* species was isolated in two

cases of fungal sinusitis in the present study also. The largest group belonged to AFRS (66.7%) followed by fungal ball (19%). Chronic indolent comprised 13% of cases and only 1.2% was under the category of acute invasive fungal sinusitis. Our observation has been quite different from Western literature as cited by the Mayo clinics review in which they reported the incidence of fungal ball to be 3.7% compared to 6.9% for allergic fungal sinusitis and 0.003% for invasive fungal sinusitis. Reports from France also showed that fungal ball of the paranasal sinuses was the most common manifestation, while in our study AFRS formed the highest percentage (66.7%) [14]. From these varied reports regarding the clinical types of fungal sinusitis, it becomes evident that AFRS is more common in warmer and humid climates as in India. Hence, there may be a close relationship between the clinical type and the prevailing geographical conditions. Similar studies in India have also found *Aspergillus flavus* to be the commonest fungal isolates from AFRS cases [7,15,16]. On the contrary, in the Western literature dematiaceous fungi like *Curvularia*, *Alternaria*, *Bipolaris* form the most common isolate in AFRS [17]. This highlights the fact that not only the clinical presentation, but the fungal organisms also differ with geographical location.

## CONCLUSION

The effective management of the fungal sinusitis requires early diagnosis, its histological classification, surgery and chemotherapy wherever appropriate. Antifungal therapy in other types and steroid therapy in AFRS are used. In our study patients showed a good response to treatment. However, the invasive group needed prolonged therapy. In understanding the epidemiology and varying diseases pattern of fungal rhinosinusitis, further studies would be required to redefine management strategies for rapid and better outcome especially for the invasive group.

## REFERENCES

1. Stammberger H. Endoscopic surgery for mycotic and chronic recurring sinusitis. *Ann Otol Rhino Laryngol* 1985;94:1-11.
2. Greval RS, Khurana S. Incidence of fungal infections in chronic maxillary sinusitis. *Indian J Pathol Microbiol* 1985;33:339-43.
3. Chapin K, deShazo RD, O'Brien M.A. new classification and diagnostic criteria for invasive fungal sinusitis. *Arch Otolaryngol Head Neck Surgery* 1997;123:181-86.
4. Ferreiro JA, Carlson BA, Cody T. Paranasal sinus fungal ball. *Head and Neck* 1997;33:481-86.
5. Vennewald T., Henaker M . Fungal colonization of the paranasal sinuses. *Mycoses* 1999;42:33-36.
6. Chakrabarti A, Sharma SC. Paranasal sinus mycoses . *The Indian journal of chest diseases and allied sciences* 2000;42:292-304.
7. Rupa V, Jacob M. Mathews MS. Clinico Pathological and mycological spectrum of Allergic Fungal sinusitis in South India. *Mycoses* 2002;45:364-67.
8. Panda NK, Chakrabarti A, Das A, Bapuraj RJ, Saravanan K. To study the prevalence of allergic fungal rhinosinusitis among the patients with chronic sinusitis. In :5<sup>th</sup> National Conference , society for Indian Human and Animal Mycologists, Abstract Bllk 2004.p51.
9. Bee-See Goh, Gendeh BS, Rose IM, Pit S, Samad SA , Prevalence of allergic fungal sinusitis in refractory chronic rhinosinusitis in Malaysians. *Otolaryngology-Head and Neck Surgery*. 2005;133:27-31.
10. Talmi YP, Goldschmie-Reouven A, Bakon M. Rhino-orbital and rhino-orbitocerebral mucormycosis. *Otolaryngology-Head and Neck Surgery* 2002;1274:22-31.
11. Wiley A, Schell MS. Histopathology of Fungal Rhinosinusitis, *Journal of Otolaryngology Clinics of North America* 2000;33:367-70.
12. Schell WA, Perfect JR. Fatal disseminated *Aspergillus fumigatus* infection in neutropenic host. *J Clin Microbiol* 1996;34:1333-36.
13. Ponikau JU, Sherris Da, Kern EB, Homburger HA, Frigas E, Gaffey TA, et al. The diagnosis and incidence of allergic fungal sinusitis. *Mayo Clin Proc* 1999;74(9):877-84.
14. Klossek JM, Serrano E, Peloquin L. Functional endoscopic sinus surgery and mycetomas of paranasal sinuses . *Laryngoscope* 1997;107:112-17.
15. Murthy JM, Sundaram C, Prasad VS. Sinocranial Aspergillosis: A form of central nervous system Aspergillosis in South India. *Mycoses* 2001;44:141-45.
16. Chakrabarti A, Sharma SC, Chander J. Epidemiology and pathogenesis of paranasal sinus mycoses. *Otolaryngol Head Neck Surg* 1992;107:745-50.
17. Ferguson BJ, Barnes L, Bernstein JM. Geographic variation in allergic fungal rhinosinusitis. *Otolaryngologic Clinics of North America* 2000;33:441-49.