



Internationally indexed journal

Indexed in Chemical Abstract Services (USA), Index copernicus, Ulrichs Directory of Periodicals, Google scholar, CABI ,DOAJ , PSOAR, EBSCO , Open J gate , Proquest , SCOPUS , EMBASE ,etc.



Rapid and Easy Publishing

The "International Journal of Pharma and Bio Sciences" (IJPBS) is an international journal in English published quarterly. The aim of IJPBS is to publish peer reviewed research and review articles rapidly without delay in the developing field of pharmaceutical and biological sciences



Pharmaceutical Sciences

- Pharmaceutics
- Novel drug delivery system
- Nanotechnology
- Pharmacology
- Pharmacognosy
- Analytical chemistry
- Pharmacy practice
- Pharmacogenomics
- Polymer sciences
- Biomaterial sciences
- Medicinal chemistry
- Natural chemistry
- Biotechnology
- Pharmacoinformatics
- Biopharmaceutics



Biological Sciences

- Biochemistry
- Biotechnology
- Bioinformatics
- Cell biology
- Microbiology
- Molecular biology
- Neurobiology
- Cytology
- Pathology
- Immunobiology

Indexed in Elsevier Bibliographic Database
(Scopus and EMBASE)
SCImago Journal Rank 0.129
Impact factor 0.67*



*Instruction to Authors visit www.ijpbs.net

For any Queries, visit "contact" of www.ijpbs.net

**MORPHOMETRIC STUDY OF MITRAL VALVE IN HUMAN HEARTS – A COMPARATIVE ANATOMICAL STUDY****DR. B. SENTHIL KUMAR ^{1*} DR. A. ANAND ²**

*1 Tutor / Research Scholar, 2- Associate Professor, Department of Anatomy
Vinayaka Mission's Kirupananda Variyaar Medical College,
NH-47, Sankari Main Road, Salem, Tamilnadu-636308*

ABSTRACT

Heart disease is one of the major causes for mortality and morbidity in our country. Cardiac valvular anomalies and abnormalities form an important factor for heart disease. The incidence of Mitral Valve Prolapse Syndrome is a silent contributor to the increasing statistics of heart disease. The aim of the study is to measure the dimensions of the mitral valve in cadaveric human hearts and compare it with autopsied heart specimens. The study involves 45 cadaveric and 15 autopsy heart specimens. The left atrium and left ventricle were cut open and valves were examined and measurements of the Mitral valves were taken using Vernier caliper. The circumference and area of mitral annulus differs by 1 cm in cadaveric heart specimens from autopsied heart specimens due to the effect of fixation whereas the annular diameter more or less equal in both specimens. The maximum length of leaflets of all cusps was high in autopsied hearts when compared with that of cadaveric hearts. The leaflet attachment of cusp was found to be high in cadaveric hearts than the autopsied heart. The present study findings of autopsied heart specimens can be applied to improve several surgical repair techniques and in valvular replacements.

KEY WORDS – Mitral valve, , Cusp, Leaflet, Scallop, Autopsied heart specimens, Cadaveric heart specimens.

**DR. B. SENTHIL KUMAR**

Tutor / Research Scholar, Department of Anatomy
Vinayaka Mission's Kirupananda Variyaar Medical College,
NH-47, Sankari Main Road, Salem, Tamilnadu-636308

**Corresponding author*

INTRODUCTION

Heart disease is one of the major causes for mortality and morbidity in India. This is primarily due to an increasing incidence of the sedentary life style of Indians. Cardiac valvular anomalies and abnormalities form an important factor for heart disease. The incidence of mitral valve Prolapse syndrome (MVPS) is a silent contributor to the increasing statistics of heart disease. Although mitral valve is described as bicuspid in standard textbooks, there are numerous instances of literature where additional clefts have been demonstrated contrary to established and conventional teaching, which could be a contributory cause for MVPS¹. The disorders involving the valves of the heart disturbs the pumping efficacy of the heart. Cadaveric organ donation acceptance of the heart tissue was 93% and that of the other organ were 94% for ocular, 87% for musculoskeletal and 89% for skin according to an Asian study². Human Mitral valve is the complex, dynamic, and highly variable structure. Mitral valve has an orifice with its supporting annulus, leaflets, a variety of tendinous chordae and papillary muscles¹. In ventricular systole the posterior part of mitral valve undergoes shortening by about 30% whereas the anterior part remains unchanged this is a crucial factor responsible for competence of mitral valve which is necessary for cardiothoracic surgeons who do procedures on mitral valve³. Shamim et al states that the dimensions of mitral valve do not show any racial difference⁴. The cusps are anterior aortic and posterior mural cusp with two commissural cusps being anteromedial and posterolateral. In some mitral valves accessory leaflets have been described in the posterior cusp⁵. A few studies indicate that there is no difference in the diameter and circumference of the mitral valve but in a study by Krishnaiah et al demonstrate that there is a marginal difference between Indian and western subjects and minimal difference between male and female also. These differences would be of paramount importance to a surgeon and will be crucial when valve replacements are being considered⁶.

AIM OF THE STUDY

To measure the dimensions of the mitral valve, the annulus and the supporting structures maintaining valve in cadaveric human hearts and compare it with autopsied heart specimens. To observe and report the variations in the cleft and scallops in each cusp of the mitral valve.

MATERIALS AND METHODS

A total of 45 adult cadaveric human hearts and 15 autopsied adult human hearts of both sexes were taken up for the study after obtaining ethical clearance from institutional ethics committee. Autopsied hearts were fixed in formalin for 3 days, measurements were taken from all the hearts on the 4th day, whereas in cadaveric hearts the measurements were taken from hearts of fresh cadavers i.e., cadavers which were embalmed for the purpose of dissection and the duration of embalming was less than a year. The study is a prospective study carried out in the department of Anatomy, VMKV Medical College.

Materials

Gauze cradle, Vernier caliper, measuring scale, hand lens, digital photographic equipment, dissecting microscope, dissecting instruments were used for the study.

Methods

The following parameters were measured

- Circumference of mitral annulus – it was taken as the sum of measurement of each cusps attached to annulus [Fig-1],
- Annular diameter – was deducted from the calculated circumference of the mitral annulus using the formula C/π cm (C- circumference of valve)⁶,
- Area of valve - was calculated using the formula $C^2 / 4\pi$ Sq.cm (C- circumference of valve)⁸
- Mitral cusps were measured from the attachment of the leaflet to the annulus,

- e) Maximum length of the valves was measured from the attached margin to free margin of the cusps
- f) The number of clefts and scallops in each cusps was closely observed with a hand lens and dissecting microscope [Fig-3& 4]

Procedure

The left atrium and the left ventricle were cut along the left border of the heart and exposed, taking care not to injure the valve. All the above mentioned parameters were taken by suspending the heart in a gauze cradle (Fig – 2).

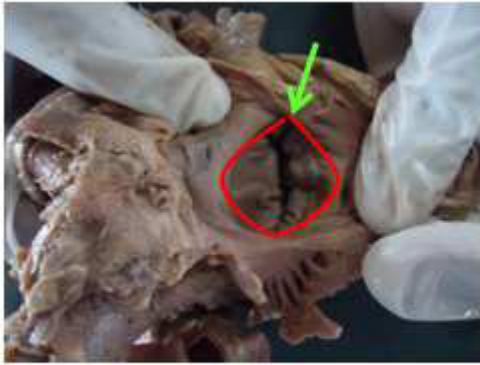

Figure - 1 Exposing the mitral Valvular components trough left atrium

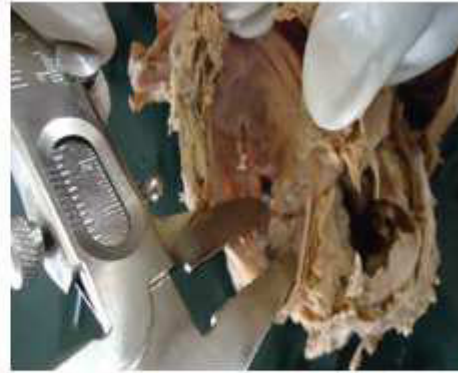

Figure - 2 Measuring the leaflets of mitral cusp

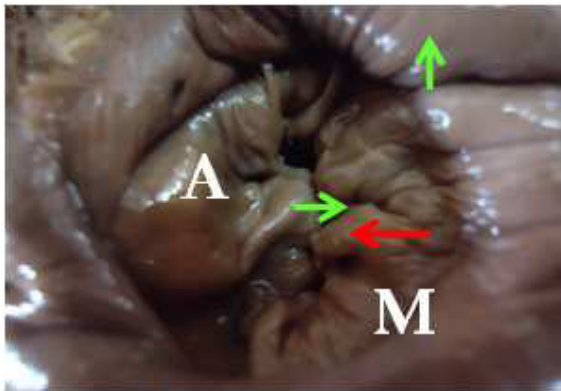


Figure - 3 Mitral Annular Orifice with cusps showing Clefts and Scallop (A – Aortic cusp, M- Mural cusp)

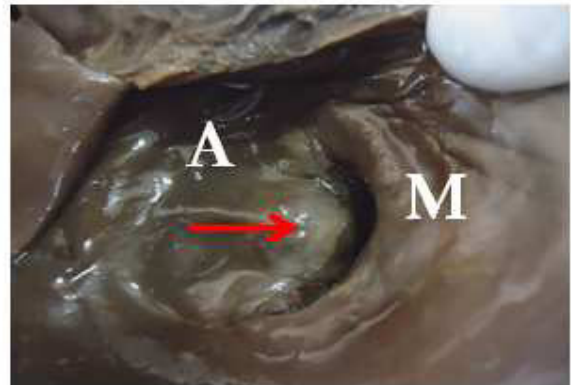


Figure - 4 Cusp showing and leaflets no clefts one Scallop

Statistical analysis

The resultant measurements obtained were statistically analyzed using SPSS software to calculate the Mean, Standard deviation, Standard error mean and P value for significance of the study.

RESULTS

The mean circumference of the mitral annulus in cadaveric hearts was less than the mean circumference in autopsied hearts and was significant [Table-1]. The annular diameter in a

cadaveric hearts was also less than that of autopsied human hearts. The mitral valve was wider in autopsied hearts [Table-1]. The measurements of attachments of leaflets of

aortic, mural, anteromedial and posterolateral leaflets were wider in cadaveric human hearts than autopsied human hearts. However the mean lengths of the leaflets were shorter in cadaveric hearts [Table -2]. The aortic cusp showed no clefts or scallop in 50% of the

specimens. In the other half it exhibited two cleft and three scallops and few with one cleft and two scallops. In the mural cusp a large number of specimens showed no cleft and only one scallop however a few specimens exhibited 4 clefts and 5 scallops [Table -3].

Table-1
Measurements of Mitral Annulus

S.no	Measurements	Mean \pm SD	
		Cadaveric Hearts (n=45)	Autopsied Hearts (n=15)
1	Circumference (cm)	7.92 \pm 0.14	8.95 \pm 0.07***
2	Annular Diameter (cm)	2.54 \pm 0.07	2.8 \pm 0.06***
3	Area (Sq.cm)	5.04 \pm 0.01	6.37 \pm 0.02***

ns – non significant, * - significant, P - value *P<0.05, **P< 0.01, ***P<0.001

Table -2
Measurement of Mitral cusps

Mitral cusps	Cusps of Cadaver heart Mean \pm SD (cm)		Cusps of Autopsy heart Mean \pm SD (cm)					
	Aortic	Mural	AM	PL	Aortic	Mural	AM	PL
Leaflets attachments	2.85 \pm 0.07	3.26 \pm 0.03	0.83 \pm 0.02	0.60 \pm 0.01	2.50 \pm 0.14***	3.13 \pm 0.01***	0.72 \pm 0.07***	0.61 \pm 0.04 ^{ns}
Maximum length of leaflets	1.63 \pm 0.02	0.95 \pm 0.07	0.73 \pm 0.09	0.65 \pm 0.07	1.80 \pm 0.14***	1.30 \pm 0.12***	0.88 \pm 0.01***	0.61 \pm 0.01*

ns – non significant, * - significant, P - value *P<0.05, **P< 0.01, ***P<0.001

Table -3
Clefts & Scallop of Mitral valves

S.no	Clefts & Scallop	No. of Specimens	
		Aortic cusp	Mural cusp
1	No cleft & 1 Scallop	27	18
2	1 cleft & 2 Scallop	6	9
3	2 cleft & 3 Scallop	27	6
4	3 cleft & 4 Scallop	0	12
5	4 cleft & 5 Scallop	0	15

DISCUSSION

Mitral valve orifice is a well defined transitional zone between left atrial wall and the left ventricle. It is smaller than the tricuspid valve with a mean circumference of 9 cm in male & 7.2 cm in female ¹. The posterior cusps and its attachment to the mitral annulus are wider than the anterior cusp of the mitral valve. Mitral regurgitation occurs only when the annulus is more than one and half dilated with an apical displacement of the posteromedial papillary

muscle, indicating that the mitral valve compensates for annular dilation because of the wide surface of its leaflets ³. In the present study the mean circumference of the mitral annulus was greater in the autopsied human hearts (8.95 \pm 0.07) cm than the cadaveric human hearts 7.92 \pm 0.14 cm statistically significant (P<0.001) which was corresponding and comparable with a study by Klues et al., in cadaveric human hearts 8.2 \pm 2.8 cm ⁹. The annular diameter in autopsied

human hearts was more than cadaveric human hearts this could have been an effect of fixation. However in Cadaveric hearts mitral valve annular diameter was about 2.54 ± 0.07 cm and in autopsied hearts it was 2.8 ± 0.06 cm significant ($P < 0.001$). Krishnaiah et al., 2011 reported the annular diameter of mitral valve orifice by echocardiographic study which was 2.19 cm in male and 1.96 cm in female, annular diameter of the present study coincides with the measurements reported by Krishnaiah et al.⁶. The measurement of mitral cusps was recorded as the leaflet attachment to the mitral annulus and also measured the maximum length of the leaflets [Table-2]. In cadaveric hearts aortic leaflet was 2.85 ± 0.07 cm, mural 3.26 ± 0.03 cm, anteromedial 0.83 ± 0.02 cm and posteromedial 0.60 ± 0.01 cm respectively. In autopsied hearts the aortic leaflet was 2.50 ± 0.14 cm, mural 3.13 ± 0.01 cm, anteromedial 0.72 ± 0.07 cm and posteromedial 0.61 ± 0.04 cm respectively when compared significant ($P < 0.001$) except posterolateral cusp was insignificant. Sakai et al., 1999 stated the attachment of aortic leaflets 3.20 ± 4.9 cm, mural 4.7 ± 3.6 cm, anterior commissural 0.7 ± 2.1 cm and posterior commissural 0.72 ± 2.1 cm whereas according to the study done by Carpentier et al., the leaflet attachments of aortic cusp was 3.2 ± 1.3 cm, other measurements showed vast difference from the measurements reported by Carpentier et al.^{7 & 10}. The maximum length of the leaflets of cadaveric heart's aortic leaflet was 1.63 ± 0.02 cm, mural 0.95 ± 0.07 cm, anteromedial 0.73 ± 0.09 cm and posteromedial 0.65 ± 0.07 cm respectively. In autopsied heart's the aortic leaflet was 1.80 ± 0.14 cm, mural 1.30 ± 0.02 cm, anteromedial 0.88 ± 0.01 cm and posteromedial 0.61 ± 0.01 cm respectively. When compared among both specimens they were highly significant ($P < 0.001$) [Table-2]. According to a study by Patil. et al., 2009 which was done in 50 human cadaveric hearts showed an average length of valve ring being 8.248 cm, the length of the free edge of valve ring was 7.362 cm and maximum length of the leaflets being anterior 1.924 cm and posterior 1.104 cm¹¹. According to a study done by Klues. et al. 1992 who measured the mitral valve in cadaveric hearts, the findings were as follows

anterior leaflet length (1.8 ± 2.8 cm) and posterior leaflet length 1.1 ± 0.2 cm⁹. In the present study the aortic cusp in 27 specimens showed no cleft and one scallop, 6 specimens with 1 cleft and 2 scallop, 27 specimens with 2 clefts and 3 scallop. The mural cusps in 18 specimens showed with no cleft and one scallop, 9 specimens with 1 cleft and 2 scallops, 6 specimens with 2 clefts and 3 scallops, 12 specimens with 3 clefts and 4 scallops, 15 specimens with 4 clefts and 5 scallops [Table-3]. The above mentioned findings collaborated with Carpentier's nomenclature. Based on his classification some were standard clefts and some were deviant clefts^{12, 13}. However in a study by Quill et al. 2009 deviant clefts were less often present than standard clefts and they were not always present at their described position¹⁴.

CONCLUSION

The mitral valve complex is a highly sophisticated structure which varies in normal anatomical presentations from individual to individual, hence the dimensions of the mitral valve and its variations will play an important role in deciding the outcome of any successful surgical intervention. So knowledge of mitral valvular apparatus and its variations can be applied to improve several surgical repair techniques involving the annulus, leaflets, chordae tendinae, and papillary muscles. The dimensions of mitral valve structure are important during surgical interventions like Valvotomy, Valve repair and prosthetic valve replacements. The knowledge of leaflets and clefts and its variations is needed for interventional procedures to repair or replace the dysfunctional valves. The effect of formalin fixation of heart specimens causes mild shrinkage of mitral valvular components and the morphometric data collected from cadaveric heart specimens cannot be applied for mitral valvular surgeries whereas the variation in clefts and scallops of leaflets can be used. The present study findings of autopsied heart specimens can be applied to improve several surgical valvular repair techniques and its replacements.

REFERENCES

1. Shah P, standing S, Gray's Anatomy- The Anatomical Basis of Clinical Practice, 39th Edn, London: Elsevier- Churchill Livingstone., 1006-1008, (2005).
2. Rodriguez Villar C, Attitude of Health Professionals toward Cadaveric Tissue Donation. Transplantation Proceeding, 41: 2064-2066.
3. Hueb, A.C. Ventricular remodeling and mitral valve modifications in dilated cardiomyopathy: New insights from anatomic study. The J Thora Cardiovasc Surg.; 124:1216-1224, (2002).
4. Shamim Akthar Cheema, Anjum Jalal, Nazeem Feroze, Jawad Sajid Khan, Dimensions of Mitral Valve of Normal Human Hearts in Pakistani Subjects, Pakistan Heart Journal ;29:32-36, (1996).
5. Chechi M A, Lees W M, Thompson R, Functional Anatomy of the Normal Mitral Valve, Journal of Thoracic Surgery;32:378-398, (1956).
6. Krishnaiah M, Mrudula C, Morphometric Study of Mitral Valve Orifice an Echo cardiographic Study, International Journal Of Pharma and Biosciences ;2:181-187, (2011).
7. Sakai T, Distance between mitral annulus and papillary muscles: anatomic study in normal human hearts. The J Thora Cardiovasc Surg; 118:636-41, (1999).
8. Howard S Richter, Mitral valve Area: Measurement soon Catheterization: Report of a Case, Circulatuion ; 28: 451-454, (1963).
9. Klues G. Diversity of structural Mitral Valve alterations in Hypertrophic Cardiomyopathy. Circulation; 85:1651-1660, (1992).
10. Carpentier A, Guerinon J, Deloche A, Fabiani JN, Relland J. Pathology of the mitral valve. In: Kalmanson D editors. The mitral valve. London: Edward Arnold; 65–77, (1976).
11. Patil D, Mehta C, Prajapati P, Morphology of Mitral Valves in Human Cadavers. The Internet Journal of Cardiology; 7:2043-2050, (2009).
12. Carpentier A. Cardiac valve surgery the French correction. J Thorac Cardiovasc Surg; 86:323–337, (1983).
13. Carpentier A, Branchini B, Cour JC, Asfaou E, Villani M, Deloche A, et al. Congenital malformations of the mitral valve in children. Pathology and surgical treatment. J Thorac Cardiovasc Surg; 72: 854–866, (1976).
14. Janson L. Quill, Alexander J. Hill, Timothy G. Laske, Ottavio Alfieri, Mitral leaflet anatomy revisited The Journal of Thoracic and Cardiovascular Surgery; 137(5) , 1077-1081, (2009).