



## QUANTITATIVE EVALUATION OF THE GINGIVAL ZENITH POSITION AND PAPILLA PROPORTIONS IN THE MAXILLARY ANTERIOR DENTITION

**DR. BHARATHI.S.R.\*<sup>1</sup>, DR .PRIYANKA K CHOLAN<sup>2</sup>, DR. PSG PRAKASH<sup>3</sup>, DR.DEVAPRIYA APPUKUTTAN<sup>2</sup>, DR. DHAYANAND JOHN VICTOR<sup>4</sup>, DR. SUMI PRIYADHARSHINI.S<sup>1</sup>**

<sup>1</sup>*Post Graduate, Department of Periodontics, SRM Dental College and Hospital, Chennai.*

<sup>2</sup>*Reader, Department of Periodontics, SRM Dental College and Hospital, Chennai.*

<sup>3</sup>*Professor, Department of Periodontics, SRM Dental College and Hospital, Chennai.*

<sup>4</sup>*Professor and Head of the Department, Department of Periodontics, SRM Dental College and Hospital, Chennai*

### ABSTRACT

Gingival morphology, contour and visibility play an essential role in creating a beautiful smile and these significant soft tissue considerations need to be established during the treatment planning requiring reconstruction or rehabilitation in the anterior esthetic zone. These anatomical landmarks show variations based on the race and ethnicity of the study population therefore, understanding and establishing the variations is a prerequisite to create a predictable esthetic smile during anterior oral rehabilitation. Keeping this objective in mind, the present study was undertaken to establish the position and to quantify the distance of gingival zenith (GZ) from the vertical bisecting midline (VBM) in the maxillary anterior tooth region. Additionally, we also aimed to quantify mesial and distal papillary proportions in relation to clinical crown length. A total of 55 subjects were recruited based on inclusion and exclusion criteria. Following which maxillary alginate impressions were made and poured with dental stone. The GZ position and the distance of GZP from VBM were measured using a digital vernier caliper under 2.5x optical magnification loupes. The mesial and distal interdental papillary heights were marked on the casts and divided by the clinical crown length to establish mesial and distal papilla proportion for each maxillary anterior tooth. On analysis it was seen that the central incisors, lateral incisors and canines showed distal displacement of 0.8mm, 0.6 mm and 0.5 mm respectively. Mean MPP and DPP for maxillary anterior dentition were 45.2% and 44.8 % respectively. The central incisors showed statistically significant difference between MPP and DPP (p value 0.026). The GZP was predominantly distally placed in relation to VBM in all the maxillary anterior teeth. The central incisors showed significant difference in mesial and distal papilla proportion, whereas canines showed a trend towards increased distal papillary height.

**KEYWORDS:** *Gingival Zenith, Vertical Bisecting Midline, Papillary Height, Papilla proportion.*



**DR. BHARATHI.S.R.\***

Post Graduate, Department of Periodontics, SRM Dental College and Hospital, Chennai.

Received on: 23-06-2017

Revised and Accepted on: 07-10-2017

DOI: <http://dx.doi.org/10.22376/ijpbs.2017.8.4.b495-501>



[Creative commons version 4.0](#)

## INTRODUCTION

Esthetics is an indispensable component in everyone's life and facial beauty is enhanced by the presence of good looking dentition.<sup>1,2</sup> Dental art is an essential element of esthetics wherein the dentist plays a major role in conserving or creating an esthetically pleasing smile. Superior restorations bounded by unappealing gingival tissues will have a negative impact on smile.<sup>3</sup> Hence, gingival architecture plays a vital role in treatment planning for the maxillary anterior dentition. Regardless of numerous efforts which were made to establish common standards, still there occurs variation among clinicians as of to what constitutes an ideal esthetic smile. The interdental papilla, which fills the interdental space not only acts as a barrier in protecting the periodontal structures but also plays a significant esthetic role. The emergence of the interdental papillae in an apicocoronal position is important during smiling as it results in positive gingival architecture esthetics.<sup>4,5</sup> The lack of harmonically shaped interdental papilla leads not only to un-esthetic black triangle formation but also to phonetic difficulty and food impaction.<sup>6,7</sup> The mathematical quantification of definite esthetic components such as gingival zenith position and interdental papillary heights in the anterior esthetic zone is achievable in order to set up a standard that is esthetically acceptable to both the patient and clinician. Gingival Zenith (GZ) termed as "Zenith Point" is an essential constituent in the smile analysis and esthetics. Even though the zenith position of the gingival tissue appears to be a minute detail, it can significantly influence the axial inclination and emergence profile of the teeth. Periodontal plastic surgical procedures provide the clinician with ample opportunities to reconstruct a pleasant gingival architecture and to correct the location of zenith position with reference to normal anatomy. Establishing the ideal location of zenith points is a vital step in alteration of mesial and distal dimensions moreover, the racial background of the subjects also has a strong influence on the gingival zenith position. Presently, there is differing and inadequate literature regarding information on where to locate the gingival zenith position from the vertical bisected midline axis of each individual maxillary anterior tooth and ideal papillary heights while creating an esthetically pleasing smile in the maxillary anterior dentition in South Indian population. Thus the objective of our study is to quantify the interdental papilla proportion mathematically as a percentage ratio of clinical crown length, thereby establishing a useful

parameter for better esthetic restorative treatment and to evaluate gingival zenith position (GZP) from the vertically bisected midline (VBM) along the long axis of each individual maxillary anterior tooth.

## MATERIALS AND METHODS

### *Study participants*

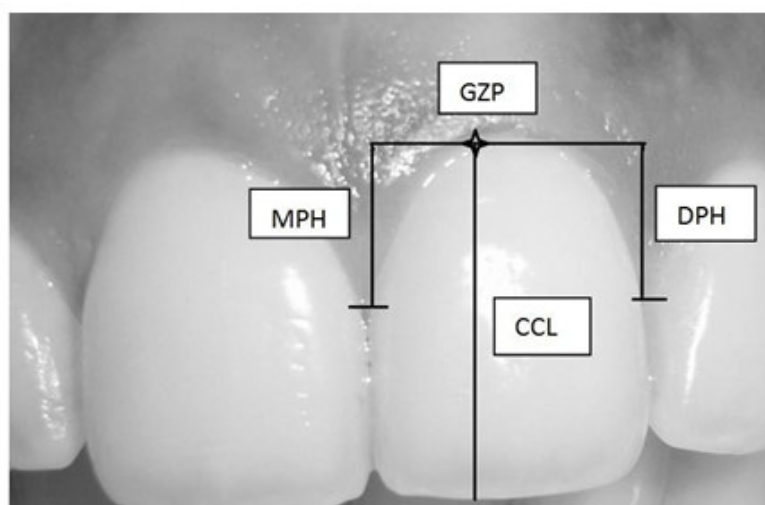
This cross sectional study was carried out in the Department of Periodontics, SRM Dental College, Chennai. The duration of study was for a period of six months from April 2016 to September 2016. The ethical clearance was approved by the Institutional review Board (SRMU/M&HS/SRMD/2016/M.D.S.-PGstudent/005) of SRM University. Convenience sampling was done and 55 consecutive subjects in the age group of 15-35 years who fitted the inclusion criteria attending the dental outpatient clinic were recruited. Subjects were informed about the nature of the study and written informed consent was obtained. Only those subjects with un-restored maxillary anterior teeth with absence of non-carious cervical lesions, attrition, spacing, crowding and without loss of interdental papillae were included. Subjects were excluded from participating in the study based on the presence of altered passive eruption, periodontal attachment loss, gingival recession, history of previous periodontal surgery, orthodontic treatment and traumatic injury or fractures on maxillary anterior teeth.

### *Study Protocol*

Maxillary arch alginate impressions were made and immediately poured with Dental stone. A digital vernier caliper (Aerospace Digimatic Vernier Calipers) was used to measure the papilla height and the distance from gingival zenith position to vertical bisecting midline of the anterior maxillary teeth, from canine to canine. Each cast was measured thrice by the same operator using 2.5 x optical loupes (Figure 1) and the average measurement was recorded. The caliper was calibrated prior to each measurement. The mesial and distal interdental papilla heights in the maxillary anterior dentition, including the central incisors, lateral incisors, and canines were measured from the level of the gingival zenith of the corresponding tooth to the tip of the papilla. Additionally, the lengths of the clinical crowns were recorded for each tooth group. Each papilla height measurement was divided by the clinical crown length of the corresponding tooth. (Figure 2) Therefore a percentage ratio was calculated by dividing the papilla height with its clinical crown length<sup>16</sup>.



**Figure 1**  
**Showing the armamentarium**



**Figure 2**  
**showing the measurements made from the level of gingival zenith to tip of Mesial Papilla (MPH) and Distal Papilla (DPH) along with Clinical Crown Length (CCL) for the maxillary left central incisor.**

To define the VBM of each clinical crown, the tooth width was measured at two reference points. The proximal incisal contact area position and the apical contact area position served as the reference points. Each width was divided in half, and the center points were marked. Center points were extended to a line toward the gingival aspect of the clinical crown to define the VBM. The highest point of the free gingival margin was marked.

## RESULTS

In our study, total of 330 maxillary anterior teeth (110 central incisors, 110 lateral incisors and 110 canines) were analyzed from the maxillary cast. Table 1 shows the descriptive statistics of gingival zenith position of left and right maxillary central incisor, lateral incisor and canine. From the above table we found that 78.1% of right central incisors showed distal displacement of GZP from VBM, 12.7% showed mesial displacement of GZP from VBM and 9.09% of population showed coincidence of GZP with the VBM whereas for the left central

incisors 76.3% of population showed distal displacement of GZP, 20% showed mesial displacement from VBM and 3.6% coincide with the VBM. Hence overall it was seen that majority of central incisors showed 77.2% of distal displacement of GZP from VBM. Similarly, 85.4% of right lateral incisors showed, distal displacement of GZP from VBM, 10.9% showed mesial displacement of GZP from VBM and 3.6% of population showed coincidence of GZP with the VBM whereas for the left lateral incisors 76.3% of population showed distal displacement of GZP, 20% showed mesial displacement from VBM and 3.6% coincide with the VBM. On observation, taken as a whole GZP of lateral incisors i.e. 77.2% were placed distal to VBM. Regarding the right canine, 40% of study population showed distal displacement of GZP from VBM, 36.3% showed mesial displacement and 23.6% showed concurrent GZP along the VBM. Left canines showed 45.4% of mesial displacement, 29% showed distal displacement and 25.4% showed concurrent GZP along the VBM. Similar to lateral incisors, the canines on the whole also mostly showed distal displacement of GZP from VBM.

**Table 1**  
**Position of gingival zenith in relation to the vertical bisected midline**

Tooth	N	MESIAL		DISTAL		COINCIDE	
		N	%	N	%	N	%
Right maxillary canine	55	20	36.3	22	40	13	23.6
Right maxillary lateral incisor	55	6	10.9	47	85.4	2	3.6
Right maxillary central incisor	55	7	12.7	43	78.1	5	9.09
Left maxillary central incisor	55	11	20	42	76.3	2	3.6
Left maxillary lateral incisor	55	23	41.8	26	47.2	6	10.9
Left maxillary canine	55	25	45.4	16	29	14	25.4
Central incisor	110	18	16.3	85	77.2	7	6.3
Lateral incisor	110	29	26.3	73	66.3	8	7.2
Canine	110	18	16.3	85	77.2	7	6.3

Table 2 shows the descriptive statistics of gingival zenith distance to the VBM of clinical crowns of maxillary anterior dentition. The mean distances of GZP to VBM of clinical crown of the right central incisor, lateral incisor and canines were 0.8mm, 0.6mm and 0.5mm respectively. The mean distances of GZP to VBM of the

clinical crown of left central incisor, lateral incisor and canines were 0.7mm, 0.6mm and 0.5mm respectively. The mean distances of GZP to VBM of the clinical crown of central incisor, lateral incisor and canines were 0.8mm, 0.6 mm and 0.5 mm respectively.

**Table 2**  
**Distance of the gingival zenith position (in mm) from the vertical bisected midline**

Tooth	N	Mean (mm)	Standard deviation (mm)	Minimum (mm)	Maximum (mm)
Right maxillary canine	55	0.53	0.377	0	1.76
Right maxillary lateral incisor	55	0.62	0.319	0	1.50
Right maxillary central incisor	55	0.81	0.384	0	1.58
Left maxillary central incisor	55	0.79	0.354	0	1.59
Left maxillary lateral incisor	55	0.61	0.301	0	1.43
Left maxillary canine	55	0.53	0.351	0	1.32
Central incisor	110	0.80	0.368	0	1.59
Lateral incisor	110	0.62	0.309	0	1.50

Table 3 shows the descriptive statistics of mesial papillary height (MPH) and distal papillary height (DPH) of maxillary anterior dentition. The MPH for the right central incisor, lateral incisor and canines were 4.19mm, 3.28mm and 4.19mm respectively. The DPH for the right central incisor, lateral incisor and canines were 3.78mm, 3.16mm and 3.92mm respectively. The MPH for left central incisor, lateral incisor and canines were 4.17mm,

3.37mm and 3.82mm respectively. The DPH for the left central incisor, lateral incisor and canines were 4.04mm, 3mm and 4.06mm respectively. The mean mesial papilla height for the maxillary anterior dentition were 3.77mm and the mean distal papilla height for the whole of maxillary anterior dentition were 3.66mm. Study results showed an increased distal papillary heights for the canines.

**Table 3**  
**Mesial and distal papilla heights (in mm) grouped by tooth position**

Tooth position	N	MPH		DPH	
		MEAN (mm)	S.D (mm)	MEAN (mm)	S.D (mm)
Right maxillary canine	55	3.81	0.082	3.92	1.15
Right maxillary lateral incisor	55	3.28	0.90	3.16	1.21
Right maxillary central incisor	55	4.19	0.95	3.78	0.68
Left maxillary central incisor	55	4.17	0.83	4.04	0.79
Left maxillary lateral incisor	55	3.37	0.75	3	0.78
Left maxillary canine	55	3.82	0.83	4.06	8.68

Table 4 shows the descriptive statistics of mesial papillary proportion (MPP) and distal papillary proportion (DPP) of maxillary anterior dentition. The MPP for the right central incisor, lateral incisor and canines were 44.7mm, 44.4mm and 47.6mm respectively whereas the DPP for the right central incisor, lateral incisor and

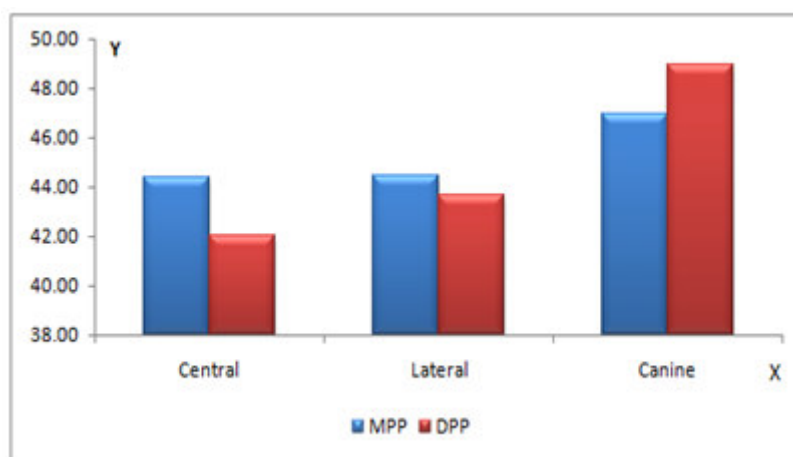
canines were 40.7 mm, 43.8mm and 48.8mm respectively. The MPP for left central incisor, lateral incisor and canines were 44.6mm, 43.8mm and 46.5mm respectively whereas the DPP for the left central incisor, lateral incisor and canines were 43.2mm, 38.9mm and 49.8mm respectively. On observation taking as a whole

of MPP for central incisor, lateral incisor and canines were 44.3mm, 44.4mm and 46.9mm respectively where as the DPP for central incisor, lateral incisor and canines were 41.9mm, 43.6mm and 48.9mm

respectively. Mean MPP for the maxillary anterior dentition were 45.2% and mean DPP for maxillary anterior dentition were 44.8% (Figure 3).

**Table 4**  
**Descriptive statistics of the mesial and distal papilla proportions grouped by tooth position**

Tooth	N	Group	Mean(mm)	S.D(mm)	Min(mm)	Max(mm)
Right Canine	55	MPP	47.6	12.54	16.1	90.6
Right Canine	55	DPP	48.8	15.6	15.8	115.2
Right Lateral incisor	55	MPP	44.4	12.9	15.7	85.5
Right lateral incisor	55	DPP	43.8	22.3	3.50	163.9
Right central incisor	55	MPP	44.7	9.8	22.5	71.8
Right central incisor	55	DPP	40.7	9.08	25.1	75.1
Left central incisor	55	MPP	44.6	10.04	3.2	73.8
Left central incisor	55	DPP	43.2	9.57	26.4	69.2
Left lateral incisor	55	MPP	43.8	13.07	22.9	79.9
Left lateral incisor	55	DPP	38.9	13.7	3.70	306.0
Left Canine	55	MPP	46.5	11.8	26.7	82.4
Left Canine	55	DPP	49.8	13.2	4.0	102.0



**Figure 3**  
**Percentage ratio of papilla height to crown length sorted by tooth group and divided into mesial ( mpp) and distal (dpp) papilla proportion.**

**Table 5**  
**Showing the MPP and DPP with statistical test for maxillary anterior dentition**

Tooth	N	MPP	DPP	t test	P value
Central incisor	110	44.3	41.9	2.251	0.026 p<0.05
Lateral incisor	110	44.4	43.6	0.253	0.801p>0.05
Canine	110	46.9	48.9	-1.436	0.154p>0.05

Table 5 shows the combined MPP and DPP values for the grouped maxillary anterior teeth and the independent t test comparing the mean values. It was observed that the central incisors showed statistically significant difference between the mesial and distal papilla proportions.

## DISCUSSION

Conventionally, the physiologic gingival architecture has been defined as a scalloped contour.<sup>6,7,8</sup> around the four surfaces of the tooth in harmony with the course of the cemento-enamel junction which is concave apically and

convex occlusally at the tip of the papilla.<sup>9,10</sup> Framing the teeth, within the limits of the gingival architecture, has an incredible impact on the aesthetics of the smile. The essential elements involved in esthetic smile designing have been greatly discussed in the literature. Gingival Zenith is defined as the most apical aspect of the free gingival margin which is esthetically important since it can greatly influence the axial inclination and emergence profile of the teeth. Details such as the GZP and the GZD of each maxillary anterior teeth can considerably manipulate the esthetic appearance of a smile. In spite of having numerous studies, literature presented differing information on where the GZP

should be placed. Knowing the GZP of each maxillary anterior tooth from the VBM can help facilitate a reference point during esthetic periodontal plastic surgical procedures. The interdental papilla is an essential factor in gingival esthetics by providing soft tissue closure between the teeth. The goal of this study was to establish a representative value for interdental papilla height of the maxillary anterior dentition which is calculated as a percentage ratio of clinical crown length, as measured from the level of the gingival zenith. Ideally, this value would be clinically applicable for practitioners determined to attain a more esthetic smile. Additionally, this value could be helpful for periodontists and implant dentists in validating and planning surgeries based on preferred vertical soft tissue height in the esthetic zone. Rufenacht et al,<sup>7</sup> proposed that the GZP was distally displaced on the central incisors and canines only, whereas those of the lateral incisors were coincident with the VBM. Goodlin et al,<sup>11</sup> described the GZP for central incisors at the distal third, laterals at the VBM, and canines ranging from the anterior third to the distal third of the VBM. Magne et al,<sup>3</sup> suggested that the GZP was distal to the long axis of all the maxillary anterior teeth. Studies conducted by Stephen and Dennis,<sup>12</sup> suggested that all central incisors displayed a distal GZP from VBM, laterals showed a deviation by 0.4 mm and GZP of canines were centralized along the long axis of the tooth. Studies conducted by Majazagar and VladoCarek,<sup>13</sup> suggested that GZ was more distally placed in lateral incisors than canines and GZ coincided with the long axis of tooth in canines. They also suggested that distal displacement is tooth dependent and hence it is larger in central incisors. Studies conducted by Diptishah and KalpeshVaishnav,<sup>4</sup> suggested that maxillary central incisors have GZP distal to VBM than that of maxillary lateral incisors while canines of both mesial, distal as well as concurrent GZP. VeenaAPatil, proposed that the mean interdental papilla heights of maxillary teeth was 3.83 mm mesially and 3.8 mm distally. Mean MPP was 43.69% ( $n = 120$ ) and DPP was 44.57% ( $n = 120$ ) and there were no significant differences found between

MPP and DPP for maxillary incisors whereas canines demonstrated increased distal papilla heights. Chu et al,<sup>16</sup> described the mean interdental papilla heights of maxillary anterior teeth were 4 mm mesially and 4.1 mm distally. MPP was 42% and DPP was 43%. No significant difference were found between MPP and DPP for maxillary incisors where as canine demonstrated increased distal papilla heights. The findings reported herein are consistent with the study done by Magne et al, 2002<sup>3</sup> where they showed distal GZP for the maxillary anterior tooth. The mean distance of GZP to VBM for central incisors, lateral incisors and canines were 0.8mm, 0.6mm and 0.5 mm respectively which are not in consistent with the study done by Dipti Shah et al<sup>14</sup> wherein they proposed the mean distance of GZP to VBM for central incisor, lateral incisor and canines as 0.9 mm, 0.5 mm and 0.3 mm respectively. Limitations of this study would be small sample size, convenience sampling, age restricted group of subject so caution in generalizability or inferring the study to the population. The strength would be the pilot or pioneering study in south Indian subjects to combine the gingival zenith position and papilla proportion to establish an esthetic guideline for maxillary anterior dentition.

## CONCLUSION

Thus to conclude within the limitations of the study it was established that maxillary anterior tooth on the whole showed distal displacement of gingival zenith position from vertical bisected midline. Among maxillary anterior tooth, central incisor showed significant difference in mesial and distal papilla proportion which might be influenced by the papillary heights whereas canines showed a trend towards increased distal papilla heights.

## CONFLICT OF INTEREST

Conflict of interest declared none.

## REFERENCES

1. Jananni M, Sivaramakrishnan M, Libby TJSurgical correction of excessive gingival display in class I vertical maxillary excess: Mucosal strip technique. *J Nat Sci Biol Med.* 2014 Jul;5(2):494-8
2. Naveen Reddy, T. Rajesh Singh, Swetha Reddy, Yadavalli Guruprasad A cross-sectional clinical study on shape of nose inner-canthal distance and geometric progression as predictors for width of the maxillary incisor teeth. *J Nat Sci Biol Med.* 2014 Jul;5(2):265-67
3. Magne P, Belser U. Bonded porcelain restorations in the anterior dentition. A biomimetic approach. *Carol Stream (IL): Quintessence;* 2002, p. 58-64
4. Takei H, Yamada H, Hau T. Maxillary anterior esthetics. Preservation of the interdental papilla. *Dent Clin North Am* 1989; 33:263-73.
5. Takei HH. The interdental space. *Dent Clin North Am* 1980;24:169-76.
6. Rufenacht CR. *Fundamentals of esthetics.* Berlin: Quintessence; 1990, p 67-134.
7. Rufenacht CR. *Principles of esthetic integration.* Chicago (IL): Quintessence; 2000, p. 154.
8. Prichard J. Gingivoplasty, gingivectomy and osseous surgery. *J Periodontol.* 1961;32:275-282.
9. Loe H, Listgarten MA, Terranova VP. The gingiva: Structure and function. In: Genco RJ, Goldman HM, Cohen DW, editors. *Contemporary periodontics.* St. Louis: C.V. Mosby; 1990. p 3-32.
10. Schroeder HE. *New York: Thieme Medical Publishers;* 1991. *Oral structural Biology;* pp. 230-32.
11. Goodlin R. Gingival aesthetics: a critical factor in smile design. *Oral Health and Dental Practice.* 2003;93(4):10-27.
12. Stephen chu, Dennis. Gingival Zenith Positions and Levels of the Maxillary Anterior Dentition. *Journal of esthetic and restorative dentistry* 2009;21(2):113-20

13. Zagar M, Zlaticar KD, Carek V. A Quantitative Evaluation of the Distal Displacement of the Gingival Zenith in the Maxillary Anterior Teeth. *CollAntropol* 2010;34: 225-28
14. Shah D, Vaishnav K, Duseja S, Agrawal P. Relative position of gingival zenith in maxillary anterior teeth- a clinical appraisal. *Int J Healthcare Biomedical Research* 2014;3(1):77-81
15. Patil V, Desai M. Assessment of gingival contours for esthetic diagnosis and treatment: A clinical study, *IndianJournal of Dental Research* 2013; 24:3.
16. Chu SJ, Tarnow DP, Tan JH, Stappert CF. Papilla proportions in the maxillary anterior dentition. *Int J Periodontics Restorative Dent* 2009;29:385-93.

## Reviewers of this article



**Dr.V.Jayanth Kumar**

Senior Lecturer,  
Dept of Oral Medicine & Radiology,  
Saveetha Dental College, Chennai, Tamilnadu,  
India.



**Dr. Deepak Moses Ravindran M.D.S.**

Faculty of Dental Sciences,  
Sri Ramachandra University,  
Porur, Chennai -116.



**Dr.Kanakam Elizabeth Thomas, M.Phil,  
Ph.D.**

Assistant Professor, Dept. of Microbiology,  
SRM Dental College, Ramapuram, Chennai  
600089, India.



**Prof.Dr.K.Suriaprabha**

Asst. Editor , International Journal  
of Pharma and Bio sciences.



**Prof.P.Muthuprasanna**

Managing Editor , International  
Journal of Pharma and Bio sciences.

**We sincerely thank the above reviewers for peer reviewing the manuscript**