



A CLINICOPATHOLOGICAL STUDY OF PILOMATRICOMA IN A TERTIARY CARE CENTRE

DR PAVITHRA P AND DR ROUMINA HASAN

¹Associate Professor, Department Of Pathology, Melaka Manipal Medical College, Manipal
²Department of Pathology, Melaka Manipal Medical College, Manipal

ABSTRACT

Pilomatricoma is a commonly misdiagnosed, rare, benign skin tumor of the hair follicle matrix. Difficulties persist in the clinical and cytological diagnosis of this lesion inspite of vast increase in the understanding of this entity since 1880. This study was undertaken to improve the preoperative diagnosis of pilomatricoma by analyzing the clinical features and cytological features wherever available. A retrospective study was conducted in a tertiary care hospital of South India over a period of four years from April 2012 to April 2016. Clinical and histopathological features of confirmed cases of pilomatricoma were studied along with the cytological features wherever available. Over a period of four years, 26 cases of pilomatricoma were reported on histopathology and fine needle aspiration cytology was performed in only 6 cases. The tumour was more common in the third decade of life with a slight female preponderance and the commonest location was the head and neck region. Clinical diagnosis of a benign skin adnexal tumor was made in only 1 case. Accurate cytological diagnosis was made only in 4 cases while 2 cases were erroneously diagnosed as epidermal inclusion cyst. Histopathology was considered the gold standard for diagnosis. A high index of clinical suspicion, cytological features of basaloid cells and shadow cells supported by calcification, giant cells, nucleated squamous cells and amorphous debris help in obtaining an accurate preoperative diagnosis though histopathology is still the gold standard.

KEYWORDS: *pilomatricoma, benign, basaloid cells, shadow cells.*



DR PAVITHRA P

Associate Professor, Department Of Pathology, Melaka Manipal
Medical College, Manipal

Received on : 24-11-2016

Revised and Accepted on 18-02-2017

DOI: <http://dx.doi.org/10.22376/ijpbs.2017.8.2.b266-269>

INTRODUCTION

Malherbe and Chenantais first described Pilomatrixoma, or calcifying epithelioma of Malherbe in 1880 as a benign subcutaneous tumor arising from the sebaceous glands.¹ Dubreuilh and Cazenave described the unique histopathological features of this neoplasm which includes epithelial cell islands and shadow cells, in the year 1922.² The term pilomatrixoma was proposed in 1961 by Forbis and Helwig.³ The term was changed to pilomatricoma in 1977.⁴ It is a relatively uncommon benign adnexal tumor which shows differentiation towards the hair matrix of the hair follicle.⁵ It shows predilection for head and neck region followed by upper extremity, trunk and lower extremity.^{6,7,8,9} It presents as an asymptomatic, firm, solitary, subcutaneous nodule.¹⁰ The aim of this study was to improve the preoperative diagnosis of pilomatricoma by analyzing the clinical features and cytological features wherever available. This helps in management of the case as surgical excision is curative.

MATERIALS AND METHODS

A retrospective study was conducted in a tertiary care hospital of South India over a period of four years from April 2012 to April 2016. All the histopathologically confirmed cases of pilomatricoma were retrieved from pathology database. Cases were analyzed for clinical, cytological and histopathological features. Papanicolaou stained cytology slides and Haematoxylin & Eosin stained histopathology slides were evaluated for the

presence of basaloid cells, shadow cells, calcification, nucleated squamous cells, foreign body giant cells, chronic inflammatory cells and amorphous debris.

RESULTS

Over a period of 4 years, 26 cases of pilomatricoma were reported on histopathology in Kasturba hospital, Manipal. The age of presentation ranged from 5 years to 70 years with a peak incidence in the age group 21- 30 years (38.46%) (Table 1). The patients affected were 14 males and 12 females (male: female=1.16:1). The sites of predilection included head and neck region (50%), upper extremity (38.46%), trunk (7.69%) and lower extremity (3.84%). Distribution of these lesions according to site and sex is given in table 2. The clinical diagnosis was epidermal inclusion cyst in 19/26 cases, neurofibroma in 2/26 cases, parasitic cyst in 1/26 and fibroxanthoma in 1/26 cases. Clinically, the probability of a benign skin adnexal tumor (pilomatricoma) was suggested in only one case. Out of 26 cases of pilomatricoma, preoperative fine needle aspiration cytology was performed in only 6 cases. Accurate cytological diagnosis of pilomatricoma was made in 3 out of 6 cases. The smears of these cases showed basaloid cells, shadow cells, foreign body giant cells and calcification in 3/3 cases, nucleated squamous cells, chronic inflammatory cells and amorphous debris in 2/3 cases. Two cases were diagnosed on cytology as epidermal inclusion cyst and the other as granulomatous reaction, which was proved on histopathology to be pilomatricoma. (Figure 1 & 2)

Table 1
Distribution of pilomatricoma in the different age groups

Age group	Number of cases
1-10	4
11-20	4
21-30	10
31-40	3
41-50	3
51-60	0
61-70	2
Total	26

Chi square value:0.857 P value *:0.931

*Chi square test with Yates correction with df4 (statistically not significant)

Table 2
Distribution of lesions according to site and sex

Site	Males	Females	Total (%)
Head and neck	6	7	13 (50%)
Upper extremity	5	5	10 (38.46%)
Trunk	2	0	2 (7.69%)
Lower extremity	1	0	1 (3.84%)
Total	14	12	26 (100%)

Chisquare value: 0.500 P value*:1.000

*Chi square test with Yates correction (statistically not significant)

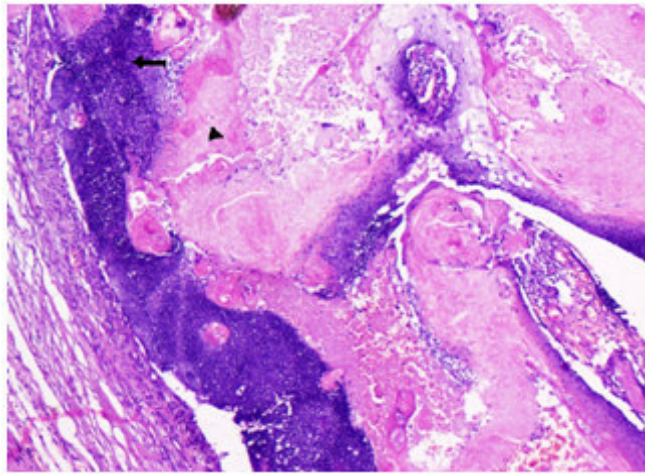


Figure 1
Photomicrograph showing basaloid cells (arrow)
and shadow cells (arrowhead) (H&E, 100x)

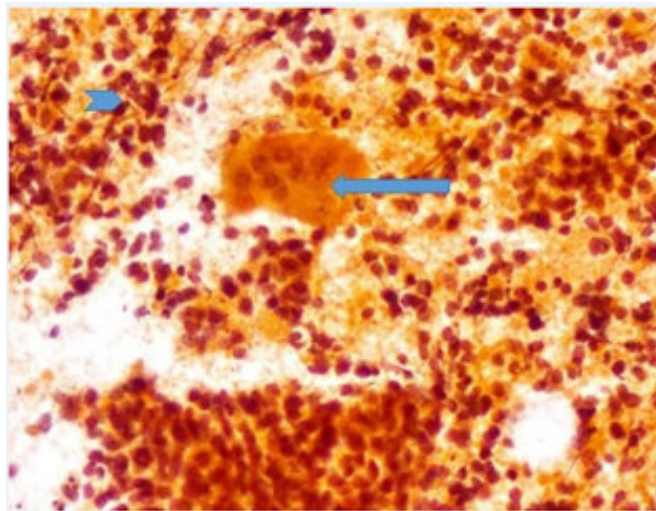


Figure 2
Cytology smear showing foreign body giant cell (arrow),
chronic inflammatory cells (arrowhead) and amorphous
debris in the background (H&E, 400x)

DISCUSSION

Pilomatricoma is an unusual, slow growing, benign skin adnexal tumor with differentiation towards hair matrix of the hair follicle.^{6, 10} It presents as an asymptomatic, firm subcutaneous nodule with occasional bluish discoloration of the overlying skin.^{6, 10} Size of the lesion varies from 0.5- 3 cms.¹¹ The commonest site of involvement is the head and neck region followed by upper extremity, trunk and lower extremity.^{12, 13} Similar observation was seen in the present study. Lan et al.¹⁴, in their study, concluded that pilomatricoma affects the age group of 1-20 years. Julian et al.¹⁵, in their study, observed bimodal presentation of pilomatricomas in 1st and 6th decades of life. In our study the peak incidence was seen in the third decade. Majority of the lesions are misdiagnosed clinically. Possible differential diagnosis for this could be epidermal inclusion cyst, dermoid cyst, brachial cleft remnants, preauricular sinuses, foreign body reaction, lipoma, degenerating fibroxanthoma, osteoma cutis, ossifying hematoma etc.¹¹ Possible reasons for this could be lack of careful

clinical examination and lack of familiarity of this rare tumor. Two pathognomonic signs which help us identify this lesion are “the tent sign”¹⁶ in which, the overlying skin when stretched, causes multiple facets and angles of the lesion and “the teeter-totter sign”¹⁷ in which pressing of one edge of the lesion causes the opposite edge to protrude from the skin. Blue red discoloration of the overlying skin definitely excludes the possibility of epidermal inclusion or dermoid cyst.¹⁷ On cytology 3/6 cases were rightly diagnosed as pilomatricoma which corresponded with histopathology. Two cases were wrongly diagnosed as epidermal inclusion cyst due to the predominance of anucleate squamous cells and absence of basaloid cells in the smears. The other case was misdiagnosed on cytology as a granulomatous reaction as the smears were composed of multinucleated foreign body giant cells, lymphocytes and histiocytes, with absence of shadow cells. The possible explanation for this is the difficulty in detaching these shadow cells on aspiration.¹⁸ Histopathology still remains the gold standard for diagnosis for pilomatricoma. It shows lobules and nests of epithelial

cells. It shows two cell types: basophilic cells in islands at the periphery of the tumour, which mature to form shadow cells towards the centre of the tumor and represent differentiation towards the hair cortex.¹⁷ This is consistent with our study. (Figure 1)

CONCLUSION

Pilomatricoma is a rare tumor which should be considered in the differential diagnosis of subcutaneous swellings of the head and neck. Its accurate diagnosis

relies on careful clinical examination, high index of suspicion and knowledge of the entire spectrum of pathological findings seen in this condition. The presence of basaloid cells, ghost cells and superficial location of the swelling, supported by calcification, giant cells and nucleated squamous cells helps in diagnosing the lesion.

CONFLICT OF INTEREST

Conflict of interest declared none.

REFERENCES

1. Malherbe A, Chenanatis J. Note sur l'epithelioma calcifiedes glandes sebacees. *Prog Med.* 1880; 8: 826– 837.
2. Dubreuilh W, Cazenave E. De l' epithelioma calcifie: etude histologique. *Ann Dermatol Syphilol.* 1922; 3: 257– 268.
3. Forbis R, Jr, Helwig EB. Pilomatricoma (calcifying epithelioma) *Arch Dermatol.* 1961 Apr; 83 (4): 606– 618.
4. Arnold HL. Pilomatricoma (letter). *Arch Dermatol.* 1977; 113:1303.
5. Gupta M, Gupta V, Kumar R, Jhaji K. Pilomatricoma: A diagnostic pitfall in fine needle aspiration cytology. *J Evol Med Dent Sci.* 2014; 3(7):1691-1697.
6. O'Connor N, Patel M, Umar T, Macpherson DW, Ethunandan M. Head and neck pilomatricoma : an analysis of 201 cases. *Br J Oral Maxillofac Surg.* 2011; 49: 354- 358.
7. Moehlenbeck FW. Pilomatricoma (calcifying epithelioma): A statistical study. *Arch Dermatol.* 1973; 108 (4): 532-534.
8. Thomas RW, Perkins JA, Ruegamer JL, Munaretto JA. Surgical excision of pilomatricoma of the head and neck: A retrospective review of 26 cases. *Ear Nose Throat J.* 1999; 78: 544- 546.
9. Danielson CA, Lin SJ, Hughes CA, An YH, Maddalozzo J. Head and neck pilomatricoma in children. *Arch Otolaryngol Head Neck Surg.* 2001;127 (12): 1481-1483.
10. Viero RM, Tani E, Skoog L. Fine needle aspiration cytology of pilomatricoma: Report of 14 cases and review of the literature. *Cytopathology.* 1999 July;10 (4): 263-269.
11. Yencha MW. Head and neck pilomatricoma in the pediatric age group: a retrospective study and literature review. *Int J Pediatr Otorhinolaryngol.* 2001 Feb;57 (2):123–128.
12. Boyd AS, Martin RW 3rd. Pathologic quiz case 1. Pilomatricoma (calcified epithelioma of Malherbe) with secondary ossification. *Arch Otolaryngol Head Neck Surg.* 1992;118: 212–215.
13. Cigliano B, Baltogiannis N, De Marco M, Faviou E, Settini A, Tilemis S, et al. Pilomatricoma in childhood: A retrospective study from three European paediatric centres. *Eur J Pediatr.* 2005 Nov;164 (11):673–677.
14. Lan MY, Lan MC, Ho CY, Li WY, Lin CZ. Pilomatricoma of the head and neck: A retrospective review of 179 cases. *Arch Otolaryngol Head Neck Surg.* 2003 Dec;129 (12): 1327–1330.
15. Julian CG, Bowers PW. A clinical review of 209 pilomatricomas. *J Am Acad Dermatol.* 1998 Aug; 39 (2): 191–195.
16. Graham JL, Merwin CF. The tent sign of pilomatricoma. *Cutis.* 1978; 22 (5): 577-580.
17. Pant I, Joshi SC, Kaur G, Kumar G. Pilomatricoma as a diagnostic pitfall in clinical practice: Report of two cases and review of literature. *Indian J Dermatol.* 2010 Oct- Dec; 55 (4): 390–392.
18. Woyke S, Olszewski w, Eichelkraut A. Pilomatricoma: a pitfall in the aspiration cytology of skin tumors. *Acta Cytol.* 1982 Mar- Apr;26(2): 189-194.

Reviewers of this article

Dr. Arijith Bishnu

Assistant Professor, Department Of
Pathology, Mekala Manipal Medical
College,
Manipal, India



Asst. Prof. Dr. Sujata Bhattacharya

Assistant Professor, School of Biological
and Environmental Sciences, Shoolini
University, Solan (HP)-173212, India



Prof. Dr. K. Suriaprabha

Asst. Editor , International Journal
of Pharma and Bio sciences.



Prof. P. Muthuprasanna

Managing Editor , International
Journal of Pharma and Bio sciences.

We sincerely thank the above reviewers for peer reviewing the manuscript