



A UNIQUE PRESENTATION OF OCCIPITAL STROKE – CHARLES BONNET SYNDROME

DR. G. NITHYALAKSHMI*¹ AND DR. S. PALANIANDAVAN²

*¹ Junior Resident , ² Professor and Head of the Department
Department of General Medicine, Sree Balaji Medical College and Hospital, India.*

ABSTRACT

Twenty percent of ischemic events in the brain involve the posterior circulation (vertebrobasilar) structures. Posterior cerebral artery stroke has interesting and varying presentations. We present to you a case of The Charles Bonnet syndrome, which refers to symptoms of visual hallucinations that occur in patients with visual acuity loss or visual field loss. While often not functionally disabling, the hallucinations can be distressing to patients and negatively impact quality of life. The underlying conditions of vision loss associated with the Charles Bonnet syndrome affect the eye, optic nerve, or brain and include a diverse set of pathologies, such as macular degeneration and stroke. This condition is often overlooked as it is self limiting and is often mistaken as psychosis, stroke and so on.

KEY WORDS: Charles bonnet syndrome, release visual hallucinations, homonymous hemianopia, PCA stroke.



***DR. G. NITHYALAKSHMI**

Junior Resident Department of General Medicine, Sree Balaji Medical College and Hospital, India.

Received on : 04-08-2016

Revised and Accepted on : 14-11-2016

DOI: <http://dx.doi.org/10.22376/ijpbs.2017.8.1.b330-332>

INTRODUCTION

The Charles Bonnet syndrome is a very rare disorder. Its prevalence has been found to be 0.5% according to a study conducted by Siraishi Y et al¹. It has been previously reported in old people with occipital stroke whose vision is severely impaired. This condition is distressing to the patient, often self limiting and frequently overlooked by clinicians. It is often misdiagnosed as psychosis or early dementia.

CASE REPORT

A 64 year old female, a known hypertensive and diabetic for 8 years, came with complaints of weakness over left upper and lower limb and deviation of angle of mouth to the right side with slurring of speech for 2 weeks. The patient was apparently normal 2 weeks back when she noticed the weakness on waking up in the morning. During the hospital stay, the patient developed vivid visual hallucinations of unknown people, children and objects like grinders and biscuits. She had insight to the hallucinations. No other sensory hallucinations were present. The patient also complained of reduced vision in both eyes. There was no history of trauma or seizures. There was no previous history of cardiac disease, CVA or TIA. Apart from Metformin and Amlodipine, patient was not on any other medications. On examination, the patient was lying comfortably, in no apparent distress. Her vitals were as follows: Temperature – 98°F, pulse rate - 90 bpm, regular, normal volume, BP- 130/80 mm of Hg. Cardiovascular, respiratory and abdominal examination were normal. Central nervous system examination revealed the following. The patient was conscious and oriented to time, place and person with an intact memory. On Mini Mental Status Exam

(MMSE), she scored 28/30 points and did not reveal mood disturbances or cognitive deficits. During examination, she had visual hallucinations of food (biscuit) which lasted for five minutes. Insight was present. The patient had mild dysphasia and a spastic gait. Motor examination showed a reduced tone and exaggerated reflexes on the left upper and lower limbs. The power was 4/5 on the left limbs. Ocular examination showed bilateral pupils measuring approximately 2mm and reacting equally to light. The visual field assessment showed loss of visual field on the left temporal and right nasal region. Her visual acuity was 6/24 on both the eyes (impaired sight). Fundus examination was suggestive of grade 4 hypertensive retinopathy. Color perception and extraocular movement were normal. Other lobar functions were normal. The patient also had the angle of her mouth deviated to the right side with loss of nasolabial fold on the left side. She was able to close both her eyelids and wrinkle her forehead. Features were suggestive of UMN type of facial palsy. Other cranial nerves examination was normal. Sensory and autonomic examination were normal.

INVESTIGATIONS

MRI brain showed large areas T2/ Flair hyperintensities involving right temporo-parietal and occipital regions. No hemorrhagic transformation was seen. Features suggestive of subacute right PCA territory infarct. EEG done revealed a normal study. The patient was started on Clopidogrel and physiotherapy for the limb weakness. Adequate glycemic control was maintained. Patient's weakness improved well. The visual hallucinations underwent spontaneous remission within 3 weeks.

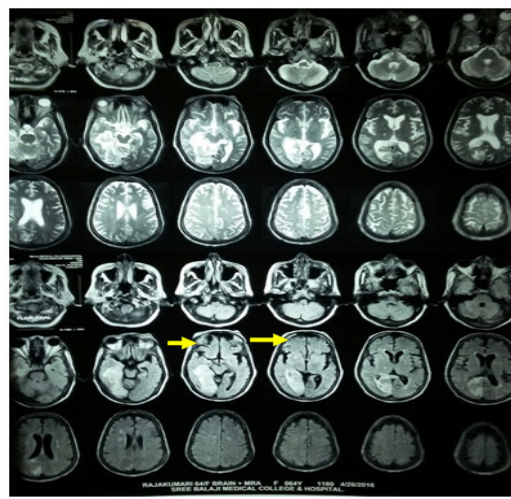


Figure 1
MRI Brain shows features suggestive of subacute right posterior cerebral

DISCUSSION

Our patient had weakness of both left limbs, mild dysarthria, complex visual hallucinations and contralateral homonymous hemianopia. She had

moderately impaired visual acuity of 6/24 due to hypertensive retinopathy and loss of visual field due to homonymous hemianopia. Visual field defects commonly occur in occipital stroke, with the type of defect depending upon the extent of occipital involvement. Unilateral involvement of PCA causes

contralateral homonymous hemianopia while bilateral occipital lobe ischemia causes cortical blindness. Complex visual hallucinations have been commonly reported in PCA stroke². In our patient, the visual hallucination is due to Charles Bonnet syndrome. Similar cases have been frequently reported in the past^{3,4}. The Charles Bonnet syndrome is a disorder with visual field defect and complex visual hallucinations in a conscious patient². It was described by Charles Bonnet in 1760². This condition has been reported in elderly

patients with severe visual impairment. Currently accepted theory suggests that loss of vision leads to visual sensory deafferentation of the visual association cortex, causing disinhibition and spontaneous firing of the visual cortical regions⁵. Another theory is the release phenomenon, where missing input to primary visual areas causes a disinhibition of visual association areas, contributing to a release of visual hallucinations⁵⁻⁶. Hence, these are also called as visual release hallucinations

The diagnostic criteria for CBS is as follows⁷⁻⁸:

- At least one complex visual hallucination within the past 4 weeks,
- A period between the first and the last hallucination exceeding 4 weeks,
- Full or partial retention of insight into the unreal nature of the hallucinations,
- Absence of hallucinations in other sensory modalities,
- Absence of delusions.

These hallucinations undergo spontaneous remission within 1 – 12 months. Reassurance needs to be provided. At present there is no established treatment. Improving vision has been thought to be the only cure. Other treatment such as antipsychotics and selective serotonin reuptake inhibitors have been used, without clear evidence. The Charles Bonnet syndrome is a diagnosis of exclusion. Visual hallucinations being misleading, other causes of complex visual hallucination, such as peduncular hallucinations, dementia, occipital lobe seizures, delirium and psychoses need to be ruled out in patients with PCA stroke complaining of visual hallucinations. The presence of insight to visual hallucinations, normal EEG and normal higher function rules out the other causes in our patient. This condition goes unrecognized at many

circumstances and needs to be addressed to alleviate the mental stress associated with this condition.

CONCLUSION

There has been an increased survival rate in stroke patients at present. This increases the morbidity associated with stroke⁹. In occipital stroke, complaints of visual hallucination are often overlooked. This case was put forward for its unique presentation and to create an awareness among physicians. The reassurance provided by the physician is essential in alleviating the mental distress associated with this condition.

CONFLICT OF INTEREST

Conflict of interest declared as none.

REFERENCES

1. Shiraishi Y, Terao T, Ibi K, Nakamura J, Tawara A. The rarity of Charles Bonnet syndrome. *J Psychiatr Res.* 2004 Mar-Apr;38(2):207-13. PubMed PMID:14757336.
2. Kumral E, Uluakay A, Dönmez İ. Charles Bonnet Syndrome in a Patient With Right Medial Occipital Lobe Infarction: Epileptic or Deafferentation Phenomenon? *Neurologist.* 2015 Jul;20(1):13-5. doi: 10.1097/NRL.000000000000037. PubMed PMID:26185956.
3. Flint AC, Loh JP, Brust JC. Vivid visual hallucinations from occipital lobe infarction. *Neurology.* 2005 Sep 13;65(5):756. PubMed PMID: 16157913.
4. Ashwin PT, Tsaloumas MD. Complex visual hallucinations (Charles Bonnet syndrome) in the hemianopic visual field following occipital infarction. *J Neurol Sci.* 2007 Dec 15;263(1-2):184-6. Epub 2007 Jun 22. PubMed PMID: 17588608.
5. Vale TC, Fernandes LC, Caramelli P. Charles Bonnet syndrome: characteristics of its visual hallucinations and differential diagnosis. *Arq Neuropsiquiatr.* 2014 May;72(5):333-6. PubMed PMID: 24863507
6. Teeple RC, Caplan JP, Stern TA. Visual hallucinations: differential diagnosis and treatment. *Prim Care Companion J Clin Psychiatry.* 2009;11(1):26-32. PubMed PMID: 19333408; PubMed Central PMCID: PMC2660156
7. Teunisse RJ, Cruysberg JR, Hoefnagels WH, Verbeek AL, Zitman FG. Visual hallucinations in psychologically normal people: Charles Bonnet's syndrome. *Lancet.* 1996 Mar 23;347(9004):794-7. PubMed PMID: 8622335
8. Jan T, Del Castillo J. Visual hallucinations: Charles Bonnet syndrome. *West J Emerg Med.* 2012 Dec;13(6):544-7. doi: 10.5811/westjem.2012.7.12891. PubMed PMID: 23357937; PubMed Central PMCID: PMC3555593
9. Ashu Aggarwal et al. Cerebral ischemic stroke: sequels of cascade. *International Journal of Pharma and Bio Sciences.* Vol.1/Issue-3/Jul-Sep.2010.