



## SCHIZENCEPHALY WITH CITROBACTER SEPTICEMIA AND ABO INCOMPATIBILITY IN A PRETERM NEONATE –CASE REPORT.

PARAMANANTHAM\*<sup>1</sup>MAHARAJA<sup>2</sup>

<sup>1</sup>*Professor of Pediatrics and Neonatology, SRM Medical College Hospital and Research Centre, Kattankulthur, Kancheepuram District, Tamilnadu, South India. Email: paramanandham59@yahoo.com*

<sup>2</sup>*Research Scholar, Department of Microbiology, SRM Medical College Hospital and Research Centre, Kattankulthur, Kancheepuram District, Tamilnadu, South India.*

### ABSTRACT

Neuronal migration defects are rare causes of seizure disorder and developmental problems. Schizencephaly, the most severe form is an extremely rare entity. Presentation and outcome of Schizencephaly are variable, but it typically presents with hemiparesis, seizures and developmental deficit. Its prevalence in India is 1.5 per one lakh population. Schizencephaly is a congenital condition, characterized by cerebrospinal fluid-filled clefts that extend from the pia surface of the cerebral hemisphere to ependymal surface of the ventricle of the brain. Magnetic Resonance Imaging is the modality of choice for its diagnosis. We present a female preterm neonate of 32 weeks gestation 1.35 kgs born to non-consanguineous parents had reduced tone of the right upper and lower limbs. Ultrasonogram of Cranium showed prominent left lateral ventricle. MRI brain presented with left open lip Schizencephaly.

**KEYWORDS:** Schizencephaly, Brain malformation, Magnetic resonance imaging.



**Dr. P. PARAMANANTHAM**

Professor of Pediatrics and Neonatology, SRM Medical College Hospital and Research Centre, Kattankulthur, Kancheepuram District, Tamilnadu, South India.

\*Corresponding author

Received on : 01-09-2016

Revised and Accepted on : 05-11-2016

DOI: <http://dx.doi.org/10.22376/ijpbs.2016.7.4.b95-97>

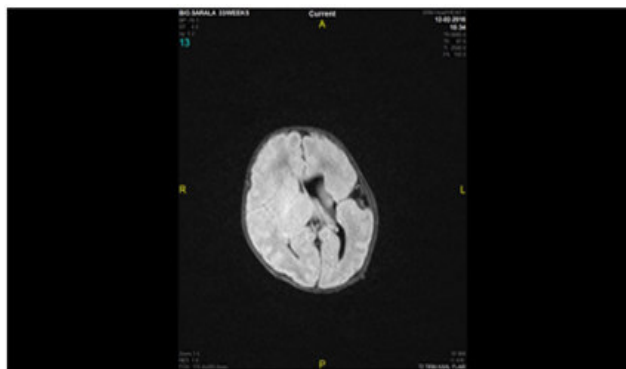
## INTRODUCTION

Schizencephaly (split brain) is a rare congenital disorder of cell migration with defect in sulcation. It is characterized by cleft in cerebral mantle, communicating between the subarachnoid spaces laterally and ventricular system medially. This disorder was originally described by Wadsworth and Yakolev in the year 1946<sup>1</sup>. Two types are recognized, have prognostic significance. In type - I or closed-lip Schizencephaly, the cleft walls are in apposition and type - II or open lip Schizencephaly, in which the walls are separated. Schizencephaly type - II more common than type I<sup>2</sup>. In either instance, the cleft is lined by heterotopic gray matter. In most cases, the gray matter along the cleft is polymicrogyric; in some instances, it is more dysplastic than polymicrogyric<sup>3</sup>. The clefts can be unilateral or bilateral, symmetric or asymmetric and can appear anywhere in the brain, although they usually are perisylvian. In unilateral cases, perusal of the contralateral hemisphere is warranted, as subtle clefts of polymicrogyria are common<sup>3</sup>.

## CASE REPORT

32 weeks female singleton baby 1.35kgs was born to a III para, hypothyroid, anemic, and PIH mother aged 24 years SRM Medical college Hospital admitted to NICU for preterm care. Other 2 elder siblings also preterms

with 1.9kg and 1.8kg subsequently. The antenatal profile was normal. The spine and cranium normal. Parents of this neonate were phenotypically normal. Routine investigation: Hemogram normal, COOMBS negative, CRP +ve (192mg), blood culture sent, indirect bilirubin total 15mg%, direct 1.2mg%, blood group of the baby - B+ve, mother - O +ve, blood smear showed toxic granules. Started on intravenous 10% Dextrose 80ml/kg and IV antibiotics Amikacin and cefotaxim. Baby had apnoeic episodes and ABO incompatibility hence caffeine citrate and double surface phototherapy given. Blood culture report came as Citrobacter positive hence antibiotic was changed to Meropenem and Amikacin. On day six, the baby had decreased tone of right upper and lower limb. Ultrasonogram of the cranium showed prominent left lateral ventricle. In view of this finding, MRI brain done which revealed left open schizencephaly. Paediatric neurologist opinion sought- open lip Schizencephaly, communicating with left lateral ventricle- A developmental anomaly. Suggested monitoring of vital signs, watch for seizures, delayed milestones, neurodevelopmental follow up and serial Doppler studies. The baby was discharged after 17 days of stay in NICU with a weight of 1.25kgs. The baby was feeding well, bilirubin normal, neonatal reflexes were normal. Advised Breast feeding to be continued, regular follow up and immunization.



**Figure**  
**MRI BRAIN SHOWING LEFT SIDE OPEN LIP SCHIZENCEPHALY**

## DISCUSSION

Schizencephaly is an extremely rare developmental disorder of the brain and Listed as RARE DISEASE by office of RARE DISEASES OF NATIONAL INSTITUTE OF HEALTH. Type 2/open lip schizencephaly is more common than type 1/fused cleft/closed cleft with 60% of unilateral Schizencephaly being of the open type.<sup>4</sup> It is, however more common in the parietal and frontal lobes. Children with unilateral schizencephaly had a mild or moderate outcome more frequently than those with bilateral lesions (62% versus 28%;  $p < 0.05$ ). Unilateral closed-lip schizencephaly was associated with the best neurodevelopmental outcome; in contrast, 11 of 12 children with bilateral open-lip clefts had severe disabilities. Language development was significantly more likely to be normal in those children with unilateral

schizencephaly than in those with bilateral cleft (48% versus 6%;  $p < 0.002$ )<sup>5</sup>. Our patient is a open lip schizencephaly communicating with left lateral ventricle. Schizencephaly is often associated with other congenital abnormalities in 50-90% of cases<sup>6</sup> such as agenesis of the septum pellucidum and corpus callosum, polymicrogyria (an excessive number of small, partly fused gyri), pachygyria (unusually thick convolutions of the cerebral cortex), heteropias (ectopic gray matter), septo-optic dysplasia and optic nerve hypoplasia.<sup>6</sup> Our patient presented with small corpus callosum. The exact etiology is not known. The likely causes may be Genetic (thought to be associated with EMX2 Gene)<sup>7</sup>. These expressed genetic factors are believed to damage the periventricular germinal matrix impairing cellular migration at 6-7 weeks of intrauterine growth. Physical insult like infection, infarction, hemorrhage, toxin and mutations. In our case, there were no stigmata of

congenital infections. MRI is the imaging modality of choice because of its superior differentiation of gray matter and white matter and its ability to image in more than one plane. Identification of gray matter lining the cleft is the pathognomonic finding<sup>2</sup>. Schizencephaly is probably a disorder of normal neuronal migration during second trimester of intrauterine development, when primitive neuron precursors (germinal-matrix) migrate from just beneath the ventricular ependyma to the peripheral hemispheres where they form the cortical grey matter. Gray matter contains neuronal cell bodies and dendrites whereas white matter contains axons which are coated in myelin<sup>8</sup>. Individuals with clefts in both hemispheres, or bilateral clefts presents with-i) developmentally delayed ii) delayed speech and language iii) corticospinal dysfunction iv) Microcephaly, mental retardation v) Seizures and spastic quadriparesis. Individuals with unilateral clefts presents with-i) hemiparesis ii) average or near average intelligence iii) seizure disorder. Treatment of Schizencephaly involves i) Physiotherapy to involved extremity in hemiparesis ii) Occupational Therapy for rehabilitation iii) Treatment of seizures with oral antiepileptics and iv) Surgical management in the form of Shunt for hydrocephalous<sup>9</sup>. Complications of

Schizencephaly are i) Optic nerve hypoplasia<sup>10</sup> ii) Skull deformity iii) Learning disability iv) seizures<sup>11</sup>.

## PROGNOSIS

The prognosis of individuals with schizencephaly varies depending on the size of neurological deficit. Bilateral clefts are associated with earlier onset of seizures that are more difficult to treat. Patients with open-lip schizencephaly die at an earlier age than those with closed-lip form.

## CONCLUSION

Schizencephaly is a rare central nervous system developmental disorder, is very often associated with other severe brain malformations and in most of the cases subsequent multiple neurological symptoms. The method of choice in diagnosis of Schizencephaly is MRI which shows the degree and type of cleft, coexisting abnormalities and allows differential diagnosis.

## CONFLICT OF INTEREST

Conflict of interest declared none.

## REFERENCES

1. Denis D, Chateil JF, Brun M, Brissaud O, Lacombe D, Fontan D, Flurin V, Pedespan J. Schizencephaly: Clinical image features in 30 infantile cases, *BrainDev* 2000;22(8):475-83.
2. Bird CR, Gilles FH. Type 1 schizencephaly: CT and neuro pathologic findings. *Am J Neuroradiol* 1987;vol 8(3):451-4.
3. Robertson R, Caruso PA, Truwit CL et al Disorders of brain development. In: *Magnetic Resonance imaging of the Brain and Spine*. Scott W. Atlas. 3<sup>rd</sup> Edition Lippincott Williams & Wilkins, 2002:356-60.
4. Donnelly LF. Schizencephaly. In: *Diagnostic Imaging Pediatrics* 1<sup>st</sup> ed., Vol 7. Salt Lake city Amirsys Publishing Inc: 2005. P.34-7.
5. <http://www.neurology.org/content/48/5/1427.short>
6. Sarnat HB, Curatolo P. *Malformations of the Nervous System* 1<sup>st</sup> ed. Edinburgh: Elsevier Publishers, Science Health Division; 2007. p.235
7. Al-Qudah-AA Clinical patterns of neuronal migration disorder and parental consanguinity. *J T Pediatr*, 1998;44(6):351-4.
8. Kapil S, More V, Vijaykumar R, Kapse S, Sonali K, Deepak K. Schizencephaly: a case report of a rare developmental disorder of brain. *International Journal of Recent Trends in Science and Technology* 2014;12(1):21-23.
9. Capra V, De Marco P, Moroni A, Faiella A, Brunelli S, Tortori-Donati P, Andreussi I, Boncinelli E, Cama A. Schizencephaly: Surgical features and new molecular genetic results. *Emr J Pediatr Surg* 1996 Dec; suppl 1:27-9.
10. Gasparetto EL, Warszawiak D, de Carvalho Neto A, Benites Filho PR, Bruck I, Antoniuk S. Septo optic dysplasia plus a case report. *Arq Neuropsiquiatr* 2003 Sep;67:1-6.
11. Hayashi N, Tsutsumi Y, Barkovich AJ. Morphological features and associated anomalies of Schizencephaly in the clinical population: detailed analysis of MR images. *Neuroradiology* 2002;44(5):418-27.